97 Heritable Disorders of Connective Tissue

Nigel P. Burrows, Franziska Ringpfeil and Jouni Uitto†

Chapter Contents

Ehlers–Danlos Syndrome 1714
Pseudoxanthoma Elasticum. 1719
Cutis Laxa 1724

Key features

- Heritable connective tissue disorders with skin involvement comprise a phenotypically diverse group of conditions
- Recognition of characteristic skin findings is often critical to establishing the diagnosis and identifying associated internal involvement, which may include life-threatening cardiovascular disease as in vascular Ehlers–Danlos syndrome and pseudoxanthoma elasticum
- Heritable connective tissue disorders can result from mutations in genes encoding structural extracellular matrix (ECM) proteins (e.g. collagens, components of elastic fibers), enzymes that modify these structural proteins, and other proteins with effects on the ECM (e.g. via transport or regulatory functions)

INTRODUCTION

Heritable connective tissue diseases manifest with a broad range of phenotypic abnormalities, including variable degrees of cutaneous and extracutaneous involvement. At one end of the spectrum, the clinical findings are mild and may be limited to the skin, while in other patients the cutaneous manifestations are part of multi-organ pathology with considerable morbidity and even mortality[1,2]. There have been significant advances in understanding the molecular bases of heritable disorders of connective tissue. This has led to improved classification and prognostication, with better recognition of the phenotypic spectra and relationships among disorders.

Connective tissue is critical for organogenesis during embryonic development and homeostatic maintenance of tissues, with complex protein assembly and cell–matrix interactions. The principal fibrillar components of the extracellular matrix (ECM) of the skin are networks consisting of collagen and elastic fibers (see Ch. 95). The study of heritable disorders of connective tissue has demonstrated the considerable impact of disruption of various individual components of the ECM and related proteins.

Classic, "primary" heritable disorders of connective tissue caused by mutations (pathogenic variants) in the genes encoding collagen and structural components of elastic fibers include several forms of Ehlers–Danlos syndrome (EDS) and cutis laxa, respectively. In addition to defects in the genes that encode these structural proteins and enzymes that modify them, seemingly unrelated pathologic processes can perturb the ECM. Examples of the latter, which can be considered as "secondary" connective tissue disorders, include pseudoxanthoma elasticum (PXE) and homocystinuria.

This chapter provides a detailed review of EDS, PXE, and cutis laxa. In addition, Marfan syndrome, homocystinuria, osteogenesis imperfecta, and Buschke–Ollendorff syndrome are presented in Table 97.1. These and other genetic diseases that affect the ECM of the skin are also summarized in Table 95.5.

EHLERS–DANLOS SYNDROME

Synonym: ▪ Cutis hyperelastica

Key features

- Clinically and genetically heterogeneous group of connective tissue disorders due to abnormalities in the synthesis and maintenance of collagens and other ECM components
- Autosomal dominant and autosomal recessive inheritance patterns
- Typical cutaneous features include hyperextensible and fragile skin, easy bruising, and poor wound healing
- Variable extracutaneous features include joint hypermobility, scoliosis, ocular changes, and, particularly in the vascular type, a significant risk of arterial, intestinal, or uterine rupture

History

Patients with features of Ehlers–Danlos syndrome (EDS) were described as early as the mid-1600s. The first comprehensive report of this condition was published in 1892 by Tschernogobow[3]. Drs Ehlers and Danlos, Danish and French dermatologists, respectively, contributed to a comprehensive clinical description in the early 1900s, and this constellation of findings became known as the Ehlers–Danlos syndrome in 1936. The genetic nature of EDS was noted in 1949, and soon thereafter it was suggested that the phenotype resulted from abnormal collagen. The genetic heterogeneity of EDS became evident in the 1960s, and molecular defects in collagen synthesis were first described in 1972[4].

In the past, EDS was divided into 11 subtypes (numbered I–XI) based primarily upon clinical features. In 1997, a consensus conference led to the revised "Villefranche nosology", which included only six subtypes[5]. Following determination of the molecular bases of other forms of EDS[6], an international classification recognizing 13 subtypes due to alterations in 19 genes was proposed in 2017[7], and an additional subtype was identified in 2018 (Table 97.2).

Epidemiology

Features suggestive of EDS (e.g. loose-jointedness) are present in a relatively large number of individuals in the general population. However, more stringent diagnostic criteria that include findings in the skin and joints, at a minimum, estimate the incidence of EDS to be ~1 in 5000.

Pathogenesis

EDS is a genetically as well as clinically heterogeneous group of connective tissue disorders that most often result from disruption of collagen fiber organization and function (Fig. 97.1). The collagen family includes 28 distinct proteins that differ in their tissue distributions and functions[8] (see Ch. 95). Approximately 90% of the collagen within the body is type I, which is expressed in almost all connective tissues and has especially important roles in the skin, tendons, and bones. Each collagen consists of three α-chain polypeptides, many of which are synthesized as precursor pro-α-chains. A trimeric collagen molecule may be either a homotrimer or heterotrimer consisting of the same versus two or three genetically different kinds of α-chains, respectively. There are 45 distinct α-chains, each encoded by a different gene[8].

The pathogenesis of EDS can involve mutations in genes for collagen-processing enzymes as well as those encoding collagen α-chains. The latter result in either dominant-negative effects, e.g. disruption of trimers and fibrils due to incorporation of mutant collagen α-chains, or haploinsufficiency. The precise phenotype depends upon the nature of the mutation(s) and the type of collagen or other protein that is affected.

Downloaded for Anonymous User (n/a) at Egyptian Knowledge Bank from ClinicalKey.com by Elsevier on March 10, 2024. For personal use only. No other uses without permission. Copyright ©2024. Elsevier Inc. All rights reserved.

ADDITIONAL HERITABLE DISORDERS OF CONNECTIVE TISSUE WITH CUTANEOUS FINDINGS				
Disease	**Cutaneous findings**	**Extracutaneous manifestations**	**Inheritance**	**Associated gene/protein product**
Marfan syndrome	Striae, elastosis perforans serpiginosa, decreased subcutaneous fat on extremities	Skeletal abnormalities (e.g. disproportionately long limbs, arachnodactyly, scoliosis), lens subluxations (upward), dilation/dissection of ascending aorta*	AD	*FBN1*/fibrillin 1 defects (the major component of microfibrils)†
Homocystinuria	Malar flush, livedo reticularis, diffuse pigmentary dilution, tissue paper-like scars	Marfanoid habitus, lens subluxations (downward), venous and arterial thrombosis‡, intellectual disability	AR	*CBS*/cystathionine synthase enzyme deficiency (resulting in increased plasma homocysteine¶); rarely, methylenetetrahydrofolate reductase, 5-methyltetrahydrofolate-homocysteine methyltransferase, or 5-methyltetrahydrofolate-homocysteine methyltransferase reductase deficiency (enzymes that convert homocysteine back to methionine)
Osteogenesis imperfecta	Thin skin	Bone fragility, blue sclerae, dentinogenesis imperfecta (in a subset of patients)	AD	*COL1A1*, *COL1A2*/type I collagen defects
Buschke–Ollendorff syndrome	Connective tissue nevi (dermatofibrosis lenticularis disseminata); occasionally cutaneous sclerosis associated with melorheostosis	Osteopoikilosis ("spotted" bones); occasionally melorheostosis (sclerotic bone resembling "dripping candle wax" on radiographs; reflects a postzygotic "second hit" in the *LEMD3* gene); rarely otosclerosis	AD	*LEMD3*/LEM domain-containing 3, an antagonist of bone morphogenic protein (BMP) and TGF-β signaling

*In addition to traditional treatment with β-blockers, angiotensin II receptor blockers (e.g. losartan), which antagonize pathogenic transforming growth factor (TGF)-β signaling, can prevent aortic root dilation in patients with Marfan syndrome; administration of doxycycline, which inhibits metalloproteinases-2 and -9, may also be of benefit.
†Mutations in the genes encoding TGF-β receptors 1 and 2 can lead to a phenotype that mimics Marfan syndrome.
‡Methionine-restricted, cysteine-supplemented diet plus pyridoxine recommended.
¶Elevated plasma homocystine and homocysteine can be detected in patients with homocystinuria, but only homocysteine is elevated in hyperhomocysteinemia.

Table 97.1 Additional heritable disorders of connective tissue with cutaneous findings. Other rare genetic diseases of the extracellular matrix are listed in Table 95.5. AD, autosomal dominant; AR, autosomal recessive.

Several forms of EDS are caused by *dominant-negative* mutations in the genes encoding α-chains of type I (*COL1A1, COL1A2*), type III (*COL3A1*), and type V (*COL5A1, COL5A2*) collagens. Characteristic examples include splice site mutations that can result in an in-frame deletion of a single exon and missense mutations that lead to a glycine substitution in the collagenous domain. The resultant polypeptides are incorporated into the polymeric collagen molecules and disrupt the formation, secretion, and/or thermal stability of triple helices. As a consequence, there may be a reduced amount of collagen as well as structurally and functionally abnormal fibrils.

Haploinsufficiency is caused by a heterozygous loss-of-function mutation, usually associated with a premature termination codon. These types of mutations often result in unstable mRNA that undergoes accelerated decay, leading to an absence of the corresponding polypeptide. Haploinsufficiency can also be caused by a missense mutation encoding a polypeptide that cannot be incorporated into collagen triple helices. Haploinsufficiency occurs when only 50% of the normal amount of collagen is present, which is not enough to form fully functional fibrils and thus results in a disease phenotype.

Vascular EDS can result from either dominant-negative mutations in *COL3A1* or haploinsufficiency of type III collagen, with the latter associated with a delayed onset of arterial complications and prolonged survival[9]. Collagen III is an important component of arterial and intestinal walls and a less abundant component of dermal connective tissue. However, a reduced amount of type III collagen leads to small or variably sized dermal collagen fibrils and thinning of the dermis, emphasizing the role of type III collagen in fibrillogenesis.

Classical EDS can be caused by dominant-negative mutations in *COL5A1* and *COL5A2* or (in 30%–50% of cases) haploinsufficiency of type V collagen (*COL5A1*). The role of type V collagen in collagen fibrillogenesis is to limit fibril diameter, explaining the ~25% increase in fibril diameter that is observed by electron microscopy in affected individuals.

Arthrochalasia EDS results from heterozygous *COL1A1* and *COL1A2* mutations that specifically affect the amino-terminal cleavage site of procollagen I N-peptidase and thereby disrupt processing of type I collagen pro-α-chains. Biallelic loss-of-function mutations in *ADAMTS2*, which encodes this procollagen I N-peptidase, are responsible for *dermatosparaxis* EDS. The latter disorder is characterized by irregular and thin collagen fibrils containing type I collagen with an intact N-propeptide, termed pN-collagen.

Kyphoscoliotic EDS is most often caused by biallelic mutations in *PLOD1*, which encodes another collagen-processing enzyme, lysyl hydroxylase; this leads to reduced hydroxylysine content in collagen polypeptides and altered cross-linking of collagen fibrils. Another form of kyphoscoliotic EDS results from biallelic mutations in *FKBP14*, which encodes an FK506-binding peptidyl-prolyl cis–trans isomerase that catalyzes collagen folding and acts as a chaperone for collagens within the endoplasmic reticulum[10].

Complete tenascin-X deficiency via biallelic null mutations underlies an autosomal recessive *classical-like EDS*[11]. Tenascin-X is an ECM protein that reinforces associations among collagen fibrils and may also regulate the structure and stability of elastic fibers. Another form of classical-like EDS is caused by mutations in *AEBP1*, which encodes an aortic carboxypeptidase-like protein (ACLP) that associates with collagens in the ECM and plays a role in both tissue repair and fibrosis[7].

Spondylodysplastic EDS can result from abnormal glycosaminoglycan processing due to mutations in genes encoding galactosyltransferases (*B4GALT6, B3GALT7*), as well as via disruption of intracellular zinc homeostasis (*SLC39A1*). In addition, defects in glycosaminoglycan biosynthesis due to mutations in dermatan-4-sulfotransferase 1 (*CHST14*) or dermatan sulfate epimerase (*DSE*) cause *musculocontractural EDS*[5]. Lastly, constitutive activation of complement 1 (*C1R, C1S*) in the classical complement pathway underlies *periodontal EDS*[12].

Clinical Features

The general features of EDS include hyperextensible fragile skin and joint hypermobility[4] (Fig. 97.2A,B). The Beighton scale can be utilized to assess the latter[13], and different subtypes of EDS have additional manifestations that facilitate their classification[5,7] (Fig. 97.3). Table 97.2 outlines the currently recognized variants of EDS.

Typical skin findings are present, to a varying degree, in all subtypes of EDS[14]. Skin hyperextensibility is defined as the ability to stretch ≥1.5 cm on the volar surface of the distal forearm or dorsum of the hand; ≥3 cm on the neck, elbow, or knee; and ≥1 cm on the palm[15]. The

Downloaded for Anonymous User (n/a) at Egyptian Knowledge Bank from ClinicalKey.com by Elsevier on March 10, 2024. For personal use only. No other uses without permission. Copyright ©2024. Elsevier Inc. All rights reserved.

2017 INTERNATIONAL CLASSIFICATION OF EHLERS–DANLOS SYNDROME			
EDS subtype	**Clinical features**	**Inheritance**	**Mutated gene/protein**
Classical*	Hyperextensible and soft/doughy skin, joint hypermobility, atrophic scars, easy bruising	AD	*COL5A1, COL5A2*/α_1- and α_2-chains of type V collagen Rarely, *COL1A1*/α_1-chain of type I collagen (associated with vascular fragility)
Classical-like, type 1	Similar to mild classical type but normal scarring; also variable muscle weakness, foot deformities	AR	*TNXB*, tenascin-X
Classical-like, type 2†	Similar to classical EDS; also foot deformities (pes planus, hallux valgus, hammer toes), osteopenia	AR	*AEBP1*/adipocyte enhancer-binding protein 1 (also known as aortic carboxypeptidase-like protein)
Cardiac valvular	Cardiac valve defects, otherwise similar to the classical type	AR	*COL1A2*/α_2-chain of type I collagen
Hypermobile*	Joint hypermobility, pain, and dislocations; less pronounced skin changes, e.g. soft/velvety, mildly hyperextensible; recurrent hernias, variable autonomic dysfunction	AD	Unknown
Vascular*	Thin, translucent skin with excessive bruising; arterial, gastrointestinal, and uterine rupture; small joint hypermobility, varicose veins, characteristic facies	AD	*COL3A1*/α_1-chain of type III collagen
Kyphoscoliotic*	Hyperextensible skin, easy bruising, joint hypermobility, kyphoscoliosis, congenital hypotonia, arterial rupture, blue sclerae, marfanoid habitus *PLOD1*: atrophic scarring, ocular fragility *FKBP14*: follicular hyperkeratosis, myopathy, impaired hearing	AR	*PLOD1*/lysyl hydroxylase‡ *FKBP14*/FK506-binding protein 14
Musculocontractural	Hyperextensible and fragile skin, wrinkled palms, congenital joint contractures, recurrent dislocations, scoliosis, ocular anomalies, craniofacial abnormalities	AR	*CHST14*/dermatan-4-sulfotransferase 1 (allelic with adducted thumb–clubfoot syndrome) *DSE*/dermatan sulfate epimerase
Arthrochalasia*	Hyperextensible and fragile skin, severe joint hypermobility with congenital bilateral hip dislocation, scoliosis	AD	*COL1A1, COL1A2*/α_1- and α_2-chains of type I collagen
Dermatosparaxis*	Severe skin fragility, sagging and redundant skin that is soft and doughy, easy bruising, joint hypermobility, short limbs, hernias, distinctive facies	AR	*ADAMTS2*/procollagen I N-peptidase
Periodontal	Mildly hyperextensible skin with prominent vessels, excessive bruising with pretibial plaques, small joint hypermobility, early-onset periodontitis with gingival recession, increased infections, marfanoid habitus	AD	*C1R, C1S*/complement C1r, C1s
Spondylodysplastic (includes former progeroid type)	Soft/doughy, translucent, and/or hyperextensible skin; variable joint hypermobility, hypotonia, limb bowing, short stature, variable tapered fingers, osteopenia, developmental delay *B4GALT6/7*: progeroid facies, joint contractures *SLC39A13*: wrinkled palms, platyspondyly, protuberant eyes	AR	*B4GALT7*/galactosyl transferase-1 *B3GALT6*/ galactosyltransferase-II *SLC39A13*/zinc transporter ZIP13
Brittle cornea syndrome	Soft, translucent skin with variable hyperextensibility and fragility, acral wrinkling, hypermobility of small joints, ocular fragility, keratoglobus/keratoconus, blue sclerae, impaired hearing, scoliosis	AR	*ZNF469*/ zinc finger protein 469 *PRDM5*/ PR domain-containing protein 5
Myopathic	Soft/doughy skin with atrophic scarring, proximal joint contractures and distal hypermobility, congenital myopathy with hypotonia that improves with age	AD or AR	*COL12A1*/α_1-chain of type XII collagen

*Six main types recognized by the 1997 Villefranche consensus classification[4].
†Described after the 2017 international classification.
‡Analysis of the urine for an increased deoxypyridinoline : pyridinoline ratio can be used as a screening test for kyphoscoliotic EDS.

Table 97.2 2017 International classification of Ehlers–Danlos syndrome (EDS)[7]. See reference 7 for full diagnostic criteria. The historical X-linked and fibronectin subtypes have unknown molecular bases and are not included in the current nosology. Other previous EDS subtypes have been reclassified as occipital horn syndrome (see Table 97.7) and familial joint hypermobility syndrome. In addition to recognized forms of EDS, heterozygous mutation in the elastin microfibril interfacer 1 (*EMILIN1*) gene was identified in a patient with increased skin elasticity, aortic aneurysms, sensorimotor peripheral neuropathy, and arthropathy. AD, autosomal dominant; ADAMTS2, *a d*isintegrin-like *a*nd *m*etalloprotease domain with *t*hrombospondin type 1 motif 2; AR, autosomal recessive; COL, collagen; PLOD1, *p*rocollagen-*l*ysine 1, 2-*o*xoglutarate 5-*d*ioxygenase 1.

skin also tends to be fragile, splitting readily due to trauma, particularly on the knees, elbows, shins, and forehead. These wounds present with a gaping, "fish-mouth" appearance; healing may be delayed and dehiscence is common. The resulting scars are typically atrophic and widen over time (Fig. 97.2C), although some affected individuals develop hypertrophic scars. Easy bruising is commonly observed, reflecting the fragility of small blood vessels. Dermatologic disorders that are associated with, but not specific to, EDS include elastosis perforans serpiginosa and piezogenic papules (Fig. 97.2D).

Major subtypes

Classical EDS is inherited in an autosomal dominant fashion and presents with hypermobile joints as well as hyperextensible and fragile skin that is prone to bruising. Scars are typically widened and atrophic, often with a "cigarette paper" appearance. The skin also tends to be soft, with a slightly doughy or velvety texture. Sites of repeated trauma develop a variety of secondary lesions such as molluscoid pseudotumors, which are fleshy nodules composed of redundant skin and fibrous tissue that favor the knees and elbows. Multiple small, hard, mobile

Downloaded for Anonymous User (n/a) at Egyptian Knowledge Bank from ClinicalKey.com by Elsevier on March 10, 2024. For personal use only. No other uses without permission. Copyright ©2024. Elsevier Inc. All rights reserved.

COLLAGEN BIOSYNTHESIS, SECRETION, AND FIBRIL ASSEMBLY – RELATIONSHIP OF PATHOLOGY TO THE MAJOR SUBTYPES OF EHLERS–DANLOS SYNDROME

Physiology		Pathology	EDS subtype (mode of inheritance)
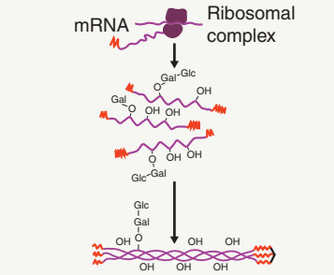	Synthesis, hydroxylation and glycosylation of pro-α polypeptides of type I, III and V collagens	**Lysyl hydroxylase** deficiency results in reduced hydroxylysine content and altered cross-linking profile	Kyphoscoliotic (AR)
	Formation of interchain S-S bonds at the carboxyl ends followed by triple helix formation	Dominant-negative mutations or haploinsufficiency in ***COL3A1*** affect triple helix formation, thermal stability, and secretion of type III collagen molecules	Vascular type (AD)
Extracellular 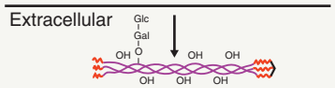	Secretion of procollagen	Dominant-negative mutations in the recognition sites for procollagen N-peptidase in ***COL1A1*** and ***COL1A2*** prevent cleavage of amino-terminal propeptides	Arthrochalasia (AD)
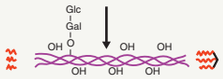	Removal of propeptides by specific proteases	Loss-of-function mutations in **procollagen-N-peptidase** result in the formation of only thin collagen fibrils	Dermatosparaxis (AR)
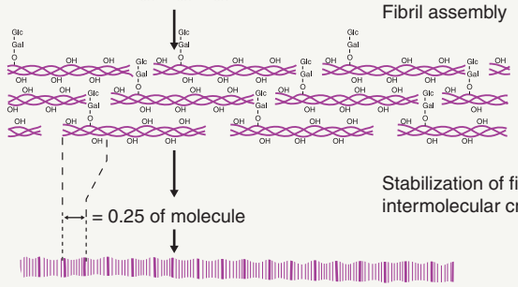	Fibril assembly	Dominant-negative mutations in ***COL5A1*** and ***COL5A2*** or haploinsufficiency in ***COL5A1*** result in abnormal or reduced amount of collagen fibrils	Classical type (AD)
	Stabilization of fibrils by intermolecular cross-linking	Absence of **tenascin-X** leads to reduced collagen fibril density	Classical type (AR)

Fig. 97.1 Collagen biosynthesis, secretion, and fibril assembly – relationship of pathology to major subtypes of Ehlers–Danlos syndrome. AD, autosomal dominant; AR, autosomal recessive; Glc-Gal, glucosyl-galactosyl residue attached to the hydroxyl group (OH) of lysine residues; S-S bonds, disulfide bonds.

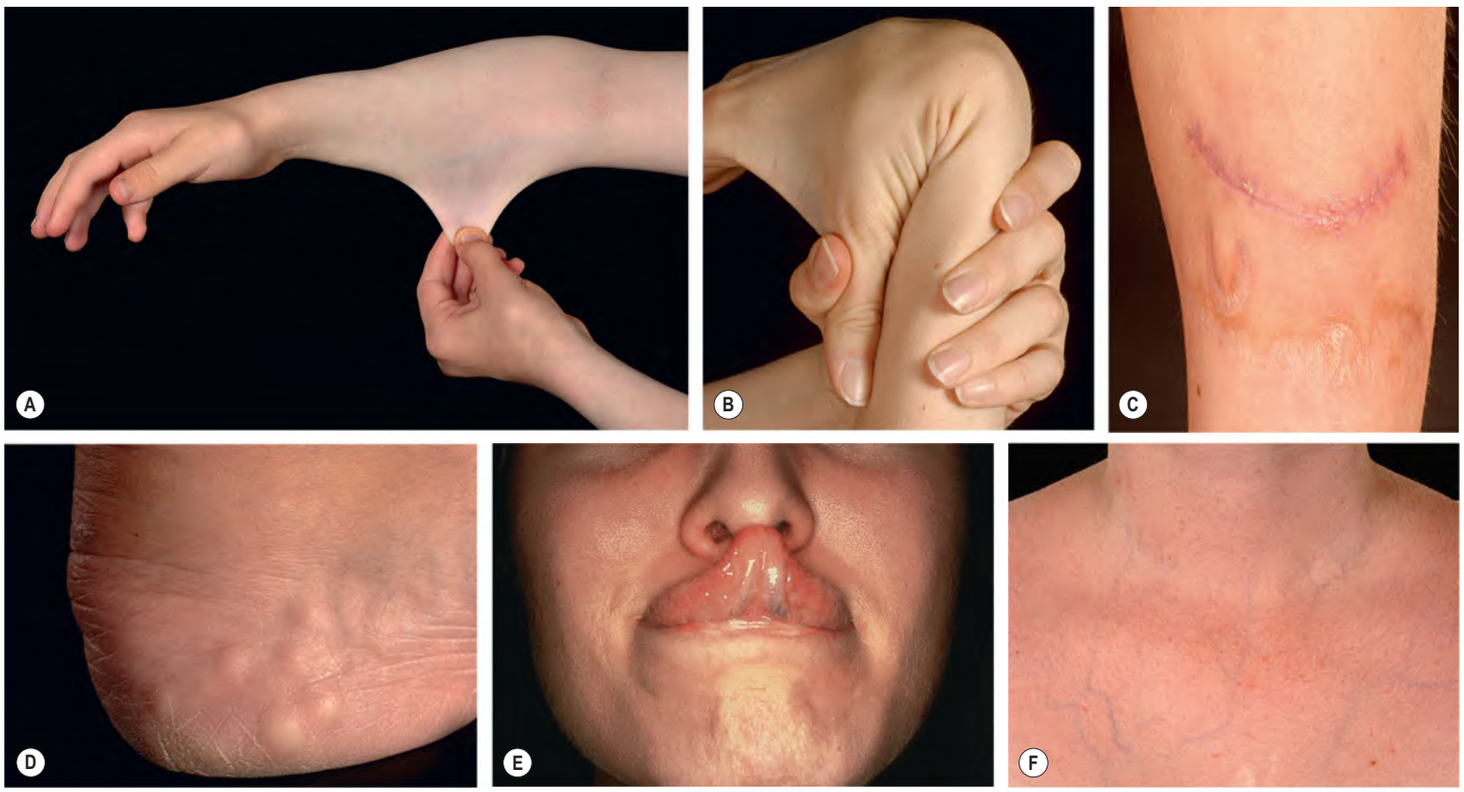

Fig. 97.2 Clinical features of Ehlers–Danlos syndrome (EDS). Patients with classical EDS demonstrating hyperextensible skin (**A**), joint hypermobility at the wrist (**B**), atrophic horseshoe-shaped scars on the shin (**C**), piezogenic papules on the heel (**D**), and the Gorlin sign (**E**). **F** Translucent skin with visible veins on the chest in a patient with vascular EDS. *A–C, F, Courtesy Addenbrooke's Hospital, Cambridge, UK.*

Downloaded for Anonymous User (n/a) at Egyptian Knowledge Bank from ClinicalKey.com by Elsevier on March 10, 2024. For personal use only. No other uses without permission. Copyright ©2024. Elsevier Inc. All rights reserved.

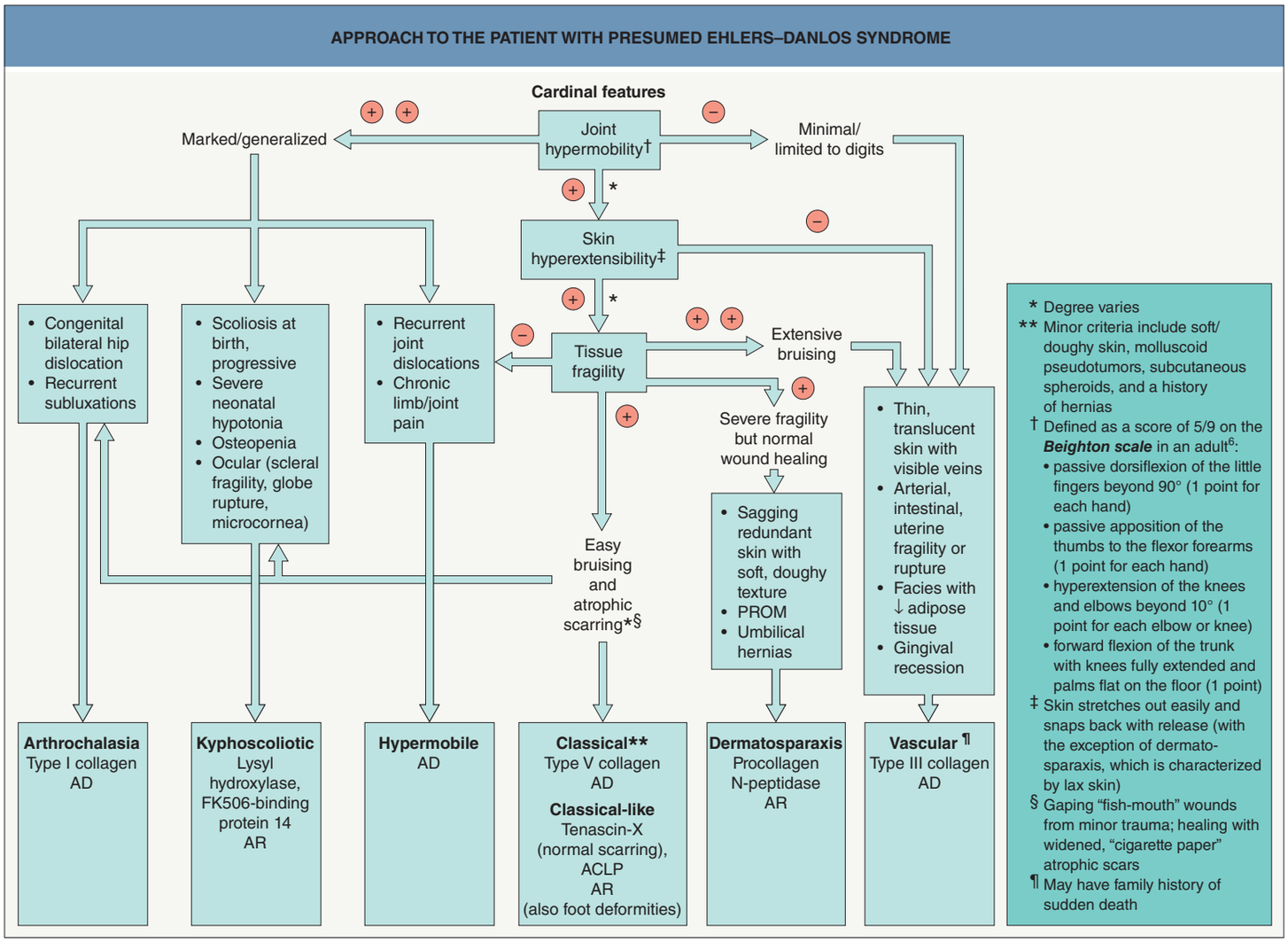

Fig. 97.3 Approach to the patient with presumed Ehlers–Danlos syndrome (EDS). See Table 97.2 for additional rare types of EDS. ACLP, aortic carboxypeptidase-like protein; AD, autosomal dominant; AR, autosomal recessive; PROM, premature rupture of fetal membranes.

papulonodules over bony prominences, such as the ulnar and tibial borders, are also a frequent finding. These subcutaneous spheroids are thought to represent calcified fat. At least half of affected individuals can touch the tip of their nose with their tongue (Gorlin sign), compared to 10% of the general population (Fig. 97.2E). Although classical EDS may be associated with mild aortic root dilation and mitral valve prolapse, each in ~5% of patients, these findings are rarely of clinical significance[16]. Other frequent musculoskeletal manifestations include pes planus, subluxations, and temporomandibular joint dysfunction.

Hypermobile EDS is the most common variant and has autosomal dominant inheritance. The most prominent clinical feature is generalized joint hypermobility, typically leading to recurrent joint dislocations that can cause chronic pain and susceptibility to osteoarthritic changes. Easy bruising is common, and the skin tends to be soft but with only mild hyperextensibility and atrophic scarring. Fatigue is common, and patients may have autonomic dysfunction presenting with orthostatic intolerance and gastrointestinal symptoms[17]; concomitant mast cell activation syndrome has also been described. The 2017 diagnostic criteria distinguish hypermobile EDS from other hypermobility spectrum disorders[18].

Vascular EDS is an autosomal dominant disorder characterized by thin translucent skin (Fig. 97.2F) with extensive bruising and a high risk of arterial, intestinal, and uterine ruptures[19]. Spontaneous arterial rupture has the highest incidence in the third and fourth decades of life but may occur earlier, especially in men, and median survival is ~50 years[9]. Affected individuals often have a characteristic facial appearance, with a "pinched" nose, thin lips, micrognathia, hollow cheeks, and prominent "staring" eyes due to decreased periorbital adipose tissue. Small earlobes and fine scalp hair are additional features.

Less common subtypes

Classical-like EDS, due to either tenascin-X or ACLP deficiency, has autosomal recessive inheritance and an overall phenotype similar to that of classical EDS. Tenascin-X deficiency is characterized by an *absence* of atrophic scarring as well as variable muscle weakness, risk of bowel rupture, and occasional association with congenital adrenal hyperplasia due to deletion of the contiguous gene encoding 21-hydroxylase[20]. Foot deformities are observed in both forms of classical-like EDS, while osteopenia is an additional feature of ACLP deficiency.

Kyphoscoliotic EDS is an autosomal recessive disorder that features skin hyperextensibility, generalized joint hypermobility, severe hypotonia at birth, delayed gross motor development, and progressive congenital scoliosis. Patients with *PLOD1* mutations have scleral fragility that can lead to rupture of the ocular globe, whereas individuals with *FKBP14* mutations present with congenital sensorineural deafness. Additional findings may include atrophic scars, easy bruising, fragility of other tissues (rarely arterial rupture), a marfanoid habitus, and osteopenia.

Arthrochalasia EDS is inherited in an autosomal dominant fashion. The major clinical features include severe generalized joint hypermobility with recurrent subluxations and congenital bilateral hip dislocation. Patients may also present with hyperextensible skin, atrophic scars, easy bruising, hypotonia, scoliosis, and mild osteopenia.

Dermatosparaxis EDS is an autosomal recessive disorder that, unlike other forms of EDS, presents with skin that is sagging and redundant as well as extremely fragile. The skin has a highly characteristic soft, doughy consistency, and it tears and bruises easily (Fig. 97.4). The clinical features of other rare forms of EDS are outlined in Table 97.2.

Downloaded for Anonymous User (n/a) at Egyptian Knowledge Bank from ClinicalKey.com by Elsevier on March 10, 2024. For personal use only. No other uses without permission. Copyright ©2024. Elsevier Inc. All rights reserved.

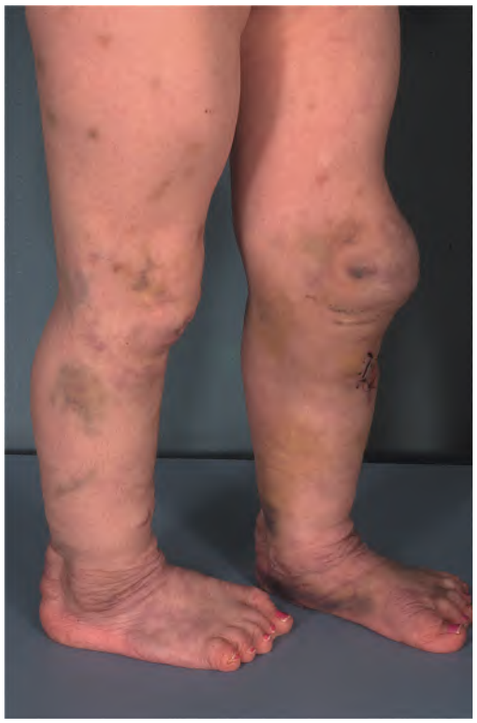

Fig. 97.4 Extensive bruising on the shins in a patient with the dermatosparaxis type of Ehlers–Danlos syndrome (EDS). Similar changes can be seen in vascular EDS. *Courtesy Julie V. Schaffer, MD.*

COMPARISON OF SELECTED CLINICAL FEATURES IN EHLERS–DANLOS SYNDROME AND MARFAN SYNDROME		
	Ehlers–Danlos syndrome	**Marfan syndrome**
Molluscoid pseudotumors	++	–
Skin	Hyperextensibility, "fish-mouth" atrophic scars	Striae
Joint hypermobility	++ (often severe)	+ (mild–moderate)
Easy bruising	++	–
Pectus excavatum	–	++
Scoliosis	+	++
High-arched palate	–	++
Ectopia lentis	+	++
Myopia	+	++
Mitral valve abnormalities	+	++
Stature	Variable	Tall

Table 97.3 Comparison of selected clinical features in Ehlers–Danlos syndrome and Marfan syndrome. ++, common feature; +, occasional feature; –, not a feature.

Pathology and Laboratory Findings

Histopathologic examination of the skin does not usually yield diagnostic findings. Nonspecific increases in elastic fibers have been reported, particularly in areas of repeated trauma or molluscoid pseudotumors. However, in vascular EDS the dermis is often reduced to ~25% of its normal thickness, and immunohistochemical staining may show intracellular accumulation of type III collagen.

Although transmission electron microscopic findings in different EDS subtypes have some overlap, collagen fibrils with variable diameters and occasional large "cauliflower" fibrils with an irregular contour are characteristic of classical EDS[21]. Ultrastructurally, arthrochalasia and dermatosparaxis types of EDS feature angular and "hieroglyphic" appearances of collagen fibrils in cross-section, respectively.

Genetic testing is available for all the major forms of EDS except the hypermobile type[22]. Additional diagnostic methods include: (1) protein electrophoresis of collagens extracted from cultured dermal fibroblasts to assess for specific collagen defects in vascular, arthrochalasia, and dermatosparaxis types of EDS; (2) urine analysis for an increased deoxypyridinoline : pyridinoline ratio in kyphoscoliotic EDS; and (3) ELISA of serum for tenascin-X deficiency[11].

Differential Diagnosis

Several previously described rare forms of EDS, including X-linked and fibronectin subtypes, are no longer included in the EDS nosology due to a lack of clear descriptions of their clinical features and unknown molecular bases. Occipital horn syndrome is now considered to represent a form of cutis laxa (see Table 97.7) rather than EDS. In contrast to cutis laxa, which is characterized by loose and sagging skin with decreased resilience, the skin of patients with EDS (except the dermatosparaxis type) retains its elasticity and recoil. Although some patients with EDS, in particular the kyphoscoliotic type, have a marfanoid body habitus, they do not typically exhibit other findings of Marfan syndrome (Table 97.3), a distinct heritable connective tissue disorder due to mutations in the fibrillin 1 gene (*FBN1*) (see Table 97.1).

The phenotype of Loeys–Dietz syndrome (LDS; formerly known as LDS type II) can mimic that of vascular EDS, with overlapping features including translucent skin, easy bruising, atrophic scarring, joint hypermobility, and arterial rupture (see Table 95.5). However, some patients with LDS have additional features such as a bifid uvula, hypertelorism, and facial milia. Patients with vascular EDS and other types that result in extensive bruising are often suspected to have a bleeding disorder, and they may present to a dermatologist after a hematologic evaluation fails to reveal any abnormalities.

Treatment

Contact sports should be avoided and the use of padding or shin guards may help to decrease trauma to the skin. Delaying suture removal for up to twice as long as usual plus use of two layers of sutures with prolonged tensile strength may improve wound healing and the appearance of surgical scars.

In vascular EDS, affected individuals are at high risk of arterial and bowel ruptures. Use of celiprolol (currently not available in the US), a long-acting β_1-antagonist with partial β_2-agonist properties, may reduce the incidence of arterial dissection; the utility of other β-blockers in vascular EDS remains to be determined[23,24]. Approximately 5% of pregnancies in women with vascular EDS are complicated by fatal uterine or arterial rupture[22]; it is unclear whether elective caesarean section reduces these risks, and patients should be managed in a high-risk obstetric unit with multidisciplinary input. Total abdominal colectomy with end ileostomy or ileorectal anastomosis are considered the safest surgical procedures after colonic perforation, with higher risks of re-perforation and anastomotic leak associated with end colostomy or restoration of colonic continuity[25].

PSEUDOXANTHOMA ELASTICUM

Synonym: ▪ Grönblad–Strandberg syndrome

Key features

- An autosomal recessive disorder characterized by clumped, distorted, and calcified elastic fibers
- Cutaneous features include yellowish papules, "cobblestoning," and redundant folds in flexural areas
- Calcification of elastic fibers in the walls of medium-sized arteries can lead to luminal narrowing and clinical sequelae such as intermittent claudication, renovascular hypertension, angina, and less commonly stroke or myocardial infarction
- Angioid streaks reflect breaks in the calcified elastic lamina of Bruch's membrane; choroidal neovascularization and hemorrhage can result in loss of visual acuity
- Gastrointestinal hemorrhage is an occasional complication

Downloaded for Anonymous User (n/a) at Egyptian Knowledge Bank from ClinicalKey.com by Elsevier on March 10, 2024. For personal use only. No other uses without permission. Copyright ©2024. Elsevier Inc. All rights reserved.

History

The French dermatologist Balzer first described the skin manifestations of PXE and associated elastic degeneration in the skin and heart in 1884, which was followed 5 years later by a similar case report by Chauffard. Based on these two cases, Darier coined the name "pseudo-xanthome élastique" in 1896 to differentiate this condition from xanthomas[26]. In the late 1920s, Grönblad[27] and Strandberg[28] recognized the association of the characteristic skin manifestations with angioid streaks, and the cardiovascular manifestations were better defined two decades later. More recently, the molecular defects that underlie PXE were identified, clarifying the mode of inheritance, which had previously been debated[29,30].

Epidemiology

PXE is an autosomal recessive disease, with a prevalence estimated to be from 1 in 25 000 to 1 in 100 000. There is no racial predilection but a slight female preponderance[31]. Skin changes of PXE usually appear during childhood or early adolescence, but the diagnosis is occasionally not made until serious arterial or ocular complications develop in the third or fourth decade of life. Mild cutaneous and ocular findings have also been observed in heterozygous carriers[24].

Pathogenesis

Loss-of-function mutations in both copies of *ABCC6* can be identified in ~90% of patients with PXE. *ABCC6* encodes an ATP-binding cassette (ABC) transporter with a high degree of homology to multidrug resistance-associated proteins. ABCC6 is predominantly expressed in the basolateral plasma membrane of hepatocytes, where it serves as an efflux pump. The absence of functional ABCC6 in PXE patients results in reduced ATP release from hepatocytes[32]. The ectonucleotide pyrophosphatase/phosphodiesterase 1 enzyme (ENPP1) converts extracellular ATP to AMP + inorganic pyrophosphate (PPi), which acts as a physiologic inhibitor of mineralization. Reduced PPi levels in PXE patients result in ectopic calcification of elastic structures in various tissues. PPi is converted to inorganic phosphate (Pi) by tissue nonspecific alkaline phosphatase (TNAP), and inhibition of this enzyme was found to increase PPi levels in a mouse model of PXE[33].

Biallelic mutations in *ENPP1* can cause *generalized arterial calcification of infancy* (GACI), a rare autosomal recessive disorder that is usually lethal during the first six months of life[34]. Occasionally, biallelic *ENPP1* mutations also cause PXE, and *ABCC6* mutations underlie a subset of GACI (GACI-2), thus demonstrating pathogenic and clinical overlap between these two conditions[34–36]. *Arterial calcification due to CD73 deficiency* (ACDC) represents a rare, milder ectopic calcification disorder caused by mutations in *NT5E*, which encodes an ecto-5′-nucleotidase that converts AMP to Pi and adenosine. The latter functions as an inhibitor of TNAP, and lower adenosine levels in ACDC lead to increased TNAP activity that then results in reduced plasma PPi levels. Clinical features of ACDC include calcification of arteries in the lower extremities and calcium hydroxyapatite deposition in juxta-articular tissues of the hands and vertebrae[37,38].

Biallelic mutations in the γ-glutamyl carboxylase gene (*GGCX*) cause PXE-like skin changes plus deficiency in vitamin K-dependent coagulation factors[39]. A combination of heterozygous mutations in *GGCX* and *ABCC6* has also been identified in patients with cutaneous findings of PXE[40]. The GGCX enzyme catalyzes the vitamin K-dependent γ-glutamyl carboxylation that is necessary for activation of coagulation factors in the liver as well as the matrix gla protein in peripheral connective tissues. When carboxylated (activated), matrix gla protein prevents ectopic mineralization.

In general, the pathogenesis of PXE and related ectopic calcification disorders is related to decreased anti-mineralization activity due to reduced plasma PPi levels. Collectively, this group has been designated as PPi deficiency syndromes[41]. Calcification of elastic fibers in the mid and deep dermis, media and intima of mid-sized arteries, and Bruch's membrane of the eye produces the characteristic clinical and histopathologic changes of PXE (Fig. 97.5).

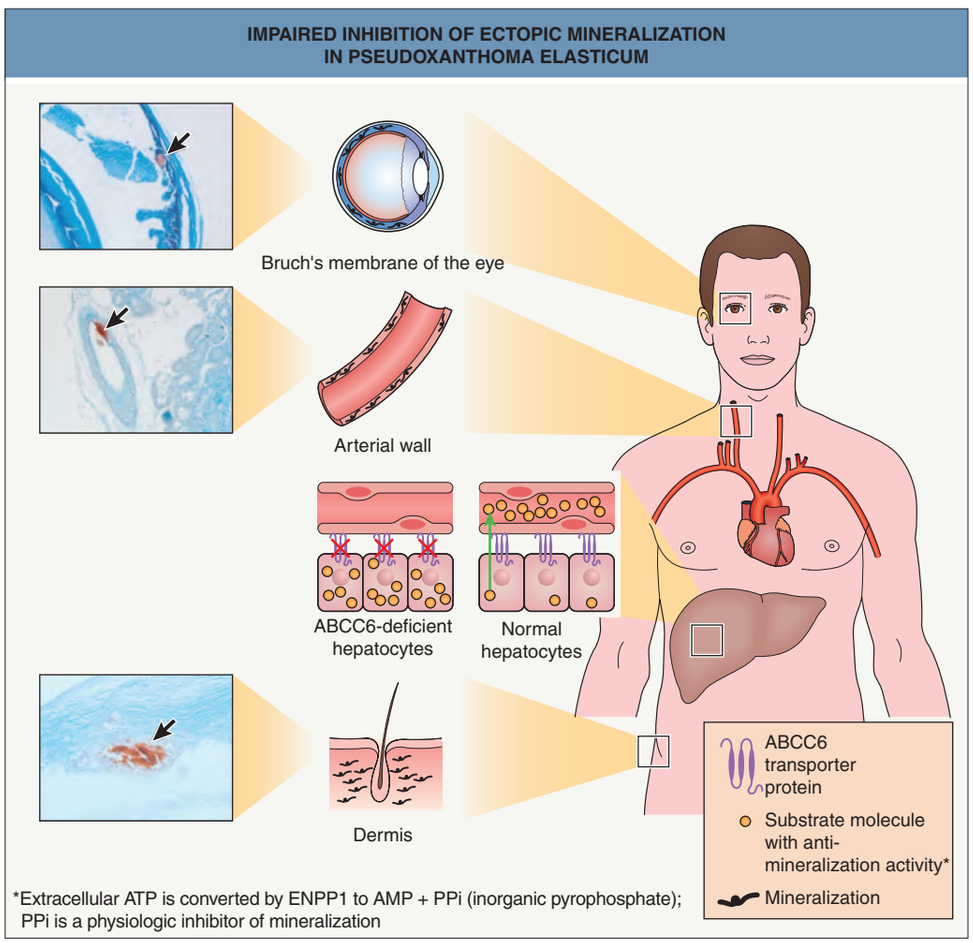

Fig. 97.5 Impaired inhibition of ectopic mineralization in pseudoxanthoma elasticum. The normal liver expresses high levels of the ABC-binding cassette subfamily C member 6 (ABCC6) protein, which serves as an efflux pump on the basolateral surface of hepatocytes, transporting molecules such as ATP from inside these cells to the extracellular space. ATP is rapidly converted to AMP and inorganic pyrophosphate (PPi), with the latter representing a physiologic anti-mineralization factor. In patients with pseudoxanthoma elasticum (PXE), an absence of ABCC6 transporter activity in the liver results in reduced circulating concentrations of PPi, which allows ectopic calcification of connective tissues in the eye, arterial walls (media and intima), and dermis. The presence of calcium is evident on histopathological examination of these tissues (alizarin red staining; see arrows in left panels) in *Abcc6*$^{-/-}$ mice, which recapitulate the features of human PXE. *Adapted from Uitto J, Li Q, Jiang Q. Pseudoxanthoma elasticum: molecular genetics and putative pathomechanisms. J Invest Dermatol 2010;130:661–70.*

Downloaded for Anonymous User (n/a) at Egyptian Knowledge Bank from ClinicalKey.com by Elsevier on March 10, 2024. For personal use only. No other uses without permission. Copyright ©2024. Elsevier Inc. All rights reserved.

Clinical Features

PXE primarily affects the elastic fiber networks of the skin, eyes, and cardiovascular system. There is tremendous variability in severity even among siblings, and sometimes only one or two of these organ systems show signs of the disease.

PXE owes its name to the characteristic cutaneous findings, which bear some resemblance to xanthomas and represent the most frequent manifestation of the condition. Thin, yellowish papules typically begin to appear in flexural areas during the first or second decade of life. Over time, the papules coalesce to form cobblestone-like plaques, giving rise to a "plucked chicken skin" or "cobblestone" appearance (Fig. 97.6). The lateral aspect of the neck is often affected first, with the antecubital and popliteal fossae, wrists, axillae, and groin being additional sites of possible involvement. The periumbilical area may be affected in multiparous women, which should not be confused with *perforating calcific elastosis*, a localized, acquired, purely cutaneous PXE-like condition (Table 97.4; see Ch. 96). Involvement of non-flexural sites can occur in patients with more extensive disease.

Fig. 97.6 Clinical features of pseudoxanthoma elasticum. A–C Yellowish papules and "cobblestoned" plaques on the neck (**A, B**) and in the antecubital fossa (**C**). **D** Pebbling of the skin as well as thickened folds on the neck. **E** Thickened, yellowish, sagging skin in the axilla (**D**). *A, C, Courtesy Addenbrooke's Hospital, Cambridge, UK; D, E, Courtesy Julie V. Schaffer, MD.*

DIFFERENTIAL DIAGNOSIS OF PSEUDOXANTHOMA ELASTICUM			
Disorder	**Patient characteristics**	**Clinical features**	**Histologic features**
Actinic elastosis	History of chronic sun exposure; lightly pigmented skin; middle-aged and older adults	Yellow to gray, thickened, lax, finely to coarsely wrinkled skin; photodistribution on the lateral forehead, neck, dorsal aspect of the forearms	Masses of basophilic, amorphous, degenerated elastic fibers in the papillary and upper reticular dermis
Late-onset focal dermal elastosis	7th–9th decades	Multiple 1- to 3-mm yellow papules; may coalesce; neck, axillae, groin, antecubital and popliteal fossae	*Increased* normal-appearing elastic fibers in the mid and deep reticular dermis
PXE-like papillary dermal elastolysis*	6th–9th decades; primarily women	Multiple 2- to 3-mm yellow or skin-colored papules coalescing to form plaques with a cobblestone appearance; neck, flexor forearms, axillae, lower abdomen, inframammary folds	*Decreased* elastic tissue in a band-like distribution in the papillary dermis, with fragmentation and clumping of elastic fibers
White fibrous papulosis of the neck*	5th–9th decades; Japanese men, White women	Multiple 2- to 3-mm whitish papules; lateral and posterior neck > upper trunk	*Decreased* elastic fibers in the papillary and mid reticular dermis; thickened collagen bundles
Elastoderma	3rd–4th decades	Localized areas of lax, pendulous skin; neck, trunk, arm	*Increased* normal- and abnormal-appearing elastic fibers throughout the dermis, extending into the subcutis
Perforating calcific elastosis†	Multiparous Black women; 5th–8th decades‡	Plaque composed of coalescing keratotic papules (most apparent at the periphery); periumbilical area¶	Transepidermal elimination of calcified, distorted elastic fibers

*Within the spectrum of fibroelastolytic diseases of the skin.
†Also referred to as periumbilical perforating PXE.
‡Occasionally associated with an increased calcium–phosphate product in the setting of chronic kidney disease.
¶Similar lesions have been reported on the breasts.

Table 97.4 Differential diagnosis of pseudoxanthoma elasticum (PXE). The differential diagnosis also includes PXE-like skin lesions in patients receiving D-penicillamine, after local exposure to saltpeter, and in chronic kidney disease. In addition, the possibility of underlying β-thalassemia, sickle cell anemia, or primary systemic amyloidosis needs to be considered.

Downloaded for Anonymous User (n/a) at Egyptian Knowledge Bank from ClinicalKey.com by Elsevier on March 10, 2024. For personal use only. No other uses without permission. Copyright ©2024. Elsevier Inc. All rights reserved.

Fig. 97.7 Mucosal lesions in pseudoxanthoma elasticum. Yellow papules on the inner aspect of the lower lip. *Courtesy Addenbrooke's Hospital, Cambridge, UK.*

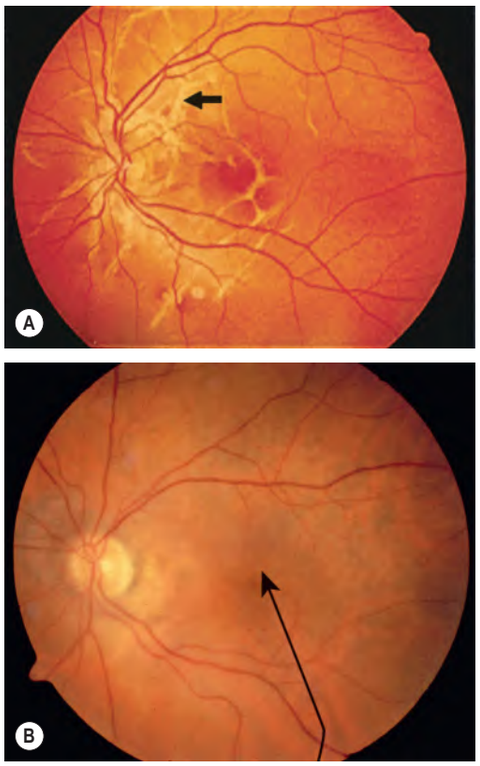

Fig. 97.8 Funduscopic findings in pseudoxanthoma elasticum (PXE). **A** Broad, lightly colored streaks (arrow) represent angioid streaks. **B** Mottling with "peau d'orange" color changes (arrow) over the entire retinal pigment epithelium, which may precede the onset of angioid streaks and represents the most common ophthalmologic finding in PXE.

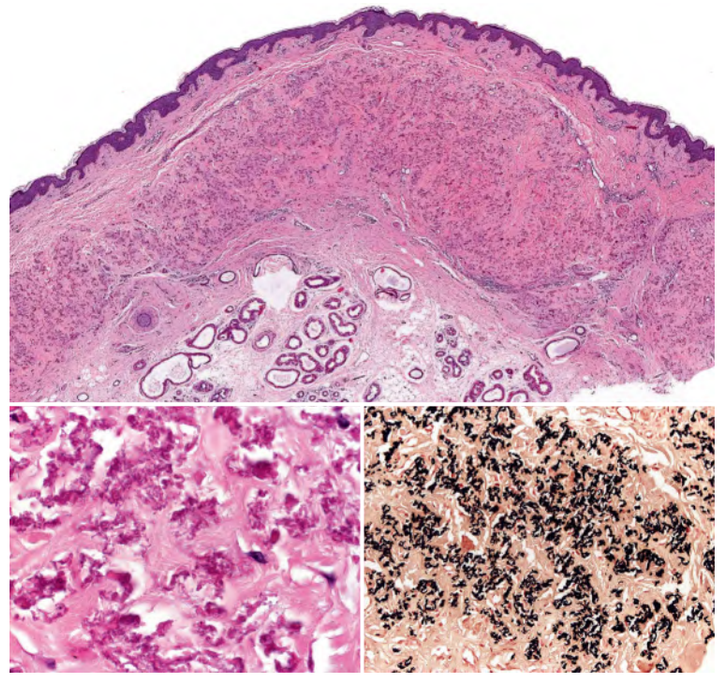

Fig. 97.9 Histopathology of pseudoxanthoma elasticum (PXE). Purple clumps in the mid and deep reticular dermis in H&E-stained sections represent calcium deposits on elastic fibers in advanced PXE (see left inset). An orcein stain highlights the clumped elastic fibers (see right inset). *Courtesy Lorenzo Cerroni, MD.*

With advanced disease, firm papules or plaques may develop due to increased dermal calcium deposition, and extrusion of this yellowish material through the epidermis as "perforating PXE" occasionally occurs. Loss of recoil due to impaired function of the elastic fiber network often leads to sagging of the skin (secondary cutis laxa), which is most notable in the axillae and groin (Fig. 97.6E). Mucosal involvement presents as yellow papules, which are most often apparent on the lower lip (Fig. 97.7). Prominent creases develop on the chin in two-thirds of affected individuals <30 years of age and the vast majority of older patients, contributing to a prematurely aged appearance[42].

The classic ocular finding in PXE is angioid streaks (Fig. 97.8A), which may be evident as early as the first decade of life and can be found in virtually all PXE patients by 30 years of age[31]. Angioid streaks are usually asymptomatic and reflect breaks in the calcified elastic lamina of Bruch's membrane, which is derived from the retina and choroid plexus. These fractures allow choroidal neovascularization, and the newly formed vessels are prone to hemorrhage with subsequent scarring. This process ultimately results in progressive loss of vision, especially within central fields, which usually becomes apparent after 40 years of age and occasionally leads to legal blindness.

Angioid streaks are highly characteristic but not pathognomonic of PXE. They can be encountered, albeit rarely, in a variety of other metabolic and heritable disorders, including Paget disease of the bone, sickle cell anemia, thalassemia, EDS and lead poisoning, as well as in the setting of age-related degeneration of Bruch's membrane. Mottling of the retinal pigment epithelium ("peau d'orange" changes; Fig. 97.8B) due to subconfluent calcification of Bruch's membrane is actually the most prevalent ophthalmologic finding in PXE and may precede the development of angioid streaks. "Coquille d'oeuf" areas reflecting more confluent calcification and "comet" lesions appearing as white bodies in the midperiphery of the fundus represent additional ocular findings that are characteristic of, but not specific to, PXE. Less commonly, macular degeneration, optic drusen, and "owl's eyes" (paired hyperpigmented spots) may be detected.

Cardiovascular manifestations of PXE often cause significant morbidity and occasionally result in premature death. PXE affects primarily mid-sized arteries, especially of the extremities, and progressive calcification of the elastic media and intima leads to the formation of atheromatous plaques. Sequelae may include intermittent claudication, loss of peripheral pulses, renovascular hypertension, angina pectoris, and less often myocardial infarction and stroke; all may occur at a younger age than in the general population. Calcified blood vessels of the gastric and intestinal mucosa have an increased propensity for hemorrhage, and even younger patients may present with gastrointestinal bleeding, particularly from the stomach[31]. Patients with PXE also have an increased prevalence of mitral valve prolapse.

Individuals with *GGCX* mutations have cutaneous, ocular, and cardiovascular findings similar to those of classic PXE. The skin manifestations tend to be more extensive and severe, with involvement of non-flexural areas of the trunk and extremities as well as redundant folds of skin that resemble cutis laxa. Loss of visual acuity secondary to ocular involvement is not typical. Additional hemorrhagic complications may occur secondary to the associated coagulation factor deficiency, including epistaxis, gingival bleeding, menorrhagia, and intracranial hemorrhage.

GACI is typically diagnosed at birth or even prenatally via ultrasound examination. Severe arterial calcification and endothelial proliferation lead to death in the first six months of life due to myocardial ischemia, hypertension, and heart failure. However, surviving children with *ENPP1* mutations may develop skin changes of PXE and angioid streaks as well as hypophosphatemic rickets due to elevated fibroblast growth factor 23 levels[34,43]. Of note, *heterozygous ENPP1* mutations underlie Cole disease, which features punctate palmoplantar keratoderma, guttate hypopigmentation, and variable ectopic calcification (see Ch. 58).

Downloaded for Anonymous User (n/a) at Egyptian Knowledge Bank from ClinicalKey.com by Elsevier on March 10, 2024. For personal use only. No other uses without permission. Copyright ©2024. Elsevier Inc. All rights reserved.

Pathology

Characteristic light microscopic changes in the skin consist of distorted, pleomorphic elastic fibers in the mid and deep reticular dermis. In advanced cases, calcium deposits on these altered elastic fibers are visible in routinely stained sections as purple clumps (Fig. 97.9). Similar changes are observed in the media of mid-sized arteries. In early disease, stains for elastin (orcein and Verhoeff–van Gieson) and calcium (alizarin red and von Kossa) are sometimes necessary to visualize the characteristic alterations in the elastic fibers. In some patients without skin manifestations who are suspected to have PXE because of other findings, such as angioid streaks, biopsy of a preexisting scar can support the diagnosis[44].

Differential Diagnosis

Diagnosis of PXE can be challenging and is often delayed for years after the initial appearance of cutaneous findings. Proposed diagnostic criteria for PXE are presented in Table 97.5[46,47]. Genetic testing of *ABCC6* can be helpful, especially in younger patients and individuals with affected family members. Considering the clinical overlap with other ectopic calcification disorders (see Pathogenesis above), additional genes such as *ENPP1* and *GGCX* should be assessed when pathogenic variants in *ABCC6* are not identified, and use of multigene panels or whole exome sequencing can increase the diagnostic yield[36].

Although characteristic skin lesions are highly suggestive of PXE in younger patients, actinic damage within chronically sun-exposed sites in older individuals may clinically mimic the yellowish plaques of lax skin in PXE. However, the latter findings involve the neck but not the axillae or groin. The differential diagnosis may also include late-onset focal dermal elastosis, PXE-like papillary dermal elastolysis, white fibrous papulosis of the neck, elastoderma, and perforating calcific elastosis (see Table 97.4).

Skin lesions with the same morphology and distribution as PXE and similar histologic features have been observed in patients receiving D-penicillamine (which interferes with desmosine cross-linking in elastin; see below)[48], after local exposure to saltpeter[49], in chronic kidney disease[50], and (historically) in L-tryptophan-induced eosinophilia myalgia syndrome[51]. There is no calcification of the abnormal fibers in D-penicillamine-induced PXE-like skin changes, whereas calcification does occur with saltpeter exposure and chronic kidney disease. Ophthalmologic and cardiovascular findings are absent and the skin lesions may resolve after cessation of the causative exposure or, in patients with renal disease, normalization of the serum calcium–phosphate product.

A PXE-like phenotype is present in up to 20% of the patients with β-thalassemia (Mediterranean populations) or sickle cell anemia[52]. Affected individuals may have characteristic cutaneous involvement as well as angioid streaks and vascular findings, but none of their siblings without a hematologic disorder have signs of PXE, and mutations in *ABCC6* have not been detected. Interestingly, downregulation of ABCC6 expression in the liver has been observed in a mouse model of β-thalassemia, suggesting a possible pathogenic mechanism[53]. PXE-like skin lesions have also been encountered in amyloid elastosis, which typically occurs in the setting of primary systemic amyloidosis; histologic examination reveals amyloid deposits that encase dermal elastic fibers, which may be short and fragmented[54].

Treatment

An approach to the multidisciplinary management of PXE is presented in Table 97.6[55–63]. Several therapies with the goal of preventing progressive mineralization are under investigation[55]. A randomized controlled clinical trial found that etidronate, a PPi analogue, may halt the progression of ectopic arterial calcification in PXE patients[64–66]. Administration of PPi orally, recombinant ENPP1, and TNAP inhibitors represent additional strategies to increase plasma PPi levels[55,67]. Other potential treatments include agents such as inositol that block calcium–phosphate deposition, sodium thiosulfate to chelate calcium,

PROPOSED DIAGNOSTIC CRITERIA FOR PSEUDOXANTHOMA ELASTICUM (PXE; 2014)
Major criteria
Skin findings
• Characteristic pseudoxanthomatous papules and plaques on the neck and/or other flexural sites • Histopathologic evidence of calcified elastic fibers in the mid and lower dermis of affected skin
Eye findings
• Angioid streak(s) >1 disc diameter in length • "Peau d'orange" changes*
Genetic testing
• Biallelic pathogenic variants in *ABCC6*
Minor criteria
• Definite PXE diagnosed in a first-degree relative (especially a sibling) • Pathogenic variant identified in one allele of *ABCC6* • Histopathologic findings of PXE in non-lesional skin
Definite PXE diagnosis* requires either**: Both major skin criteria plus one major eye criterion ***-or- Major genetic criterion ***Probable PXE diagnosis in an individual with an affected first-degree relative* requires either**: Both major skin criteria ***-or-*** One major eye criterion ***Minor criteria can be helpful in suggesting a possible PXE diagnosis***
*In an individual <20 years of age.

Table 97.5 Proposed diagnostic criteria for pseudoxanthoma elasticum (PXE; 2014)[46,47].

A MULTIDISCIPLINARY APPROACH TO MANAGEMENT OF PSEUDOXANTHOMA ELASTICUM
Skin
• No specific treatment is available • Surgical intervention for excessive skin folds[58]
Eyes
Prevention and early detection
• Annual funduscopic examination • Regular use of an Amsler grid to assess for central visual field defects • Use of sunglasses • Diet/vitamins rich in antioxidants • Avoidance of head trauma, heavy straining, and smoking; limited participation in contact and racket sports
Treatment
• Intravitreal injections of VEGF antagonists (e.g. bevacizumab, ranibizumab, aflibercept) to prevent retinal neovascularization (but not mineralization); may stabilize or improve visual acuity[56,57,59,60]
Cardiovascular system
Prevention and early detection
• Baseline electrocardiogram and echocardiogram • Annual cardiovascular examination • Healthy lifestyle with balanced diet, regular exercise, weight control, and avoidance of smoking and excessive alcohol intake • Magnesium supplementation* (e.g. magnesium oxide or citrate)[61–63] • Moderate calcium intake (as appropriate for age) • Low-dose therapy with acetylsalicylic acid if not contraindicated
Treatment
• Correction of hyperlipidemia and hypertension • Low-dose acetylsalicylic acid, pentoxifylline, cilostazol, or clopidogrel for intermittent claudication
*A diet high in magnesium was shown to reduce connective tissue mineralization in a mouse model of PXE[62], and a non-significant trend toward reduced calcification of skin elastic fibers was observed in PXE patients who received magnesium oxide in a small randomized placebo-controlled trial[63].

Table 97.6 A multidisciplinary approach to management of pseudoxanthoma elasticum. VEGF, vascular endothelial growth factor.

Downloaded for Anonymous User (n/a) at Egyptian Knowledge Bank from ClinicalKey.com by Elsevier on March 10, 2024. For personal use only. No other uses without permission. Copyright ©2024. Elsevier Inc. All rights reserved.

and phenylbutyrate to promote maturation of mutant ABCC6[55,68,69]. Overactivation of the DNA damage response/PARP1 pathway has been implicated in aberrant mineralization, and minocycline was recently found to attenuate this signaling and reduce ectopic calcification in PXE fibroblasts as well as *Abcc6*$^{-/-}$ mice and zebrafish[70,71].

Resources for patients and families include PXE International (www.pxe.org), which provides information on ectopic calcification disorders and their management[72].

CUTIS LAXA

Synonyms: ■ Dermatochalasia ■ Dermatomegaly ■ Generalized elastolysis ■ Generalized elastorrhexis

Key features

- Group of conditions characterized by sparse and fragmented elastic fibers
- Both heritable (autosomal dominant, autosomal recessive, and X-linked recessive) and acquired forms
- Features loose, sagging skin with reduced resilience and recoil
- Extracutaneous manifestations include emphysema, arterial and cardiac valvular abnormalities, hernias, diverticula, and craniofacial anomalies

History

The clinical differences between cutis laxa (CL) and EDS were delineated in 1923 by F. Parkes Weber[3], and the generalized nature of the elastolysis and potential for internal involvement were recognized by Goltz and co-workers in 1965[73].

Epidemiology

The heritable forms of CL are rare and no precise estimate of their prevalence is available. There appears to be no racial or ethnic predilection, and inheritance can be autosomal dominant, autosomal recessive, or X-linked recessive. Heritable CL is typically apparent at birth or during early childhood, but the development of lax skin is occasionally delayed until early adulthood in autosomal dominant forms. Acquired CL frequently has a later onset.

Pathogenesis

CL represents a disorder of the elastic fiber network and can involve multiple tissues, including internal organs as well as the skin. Insights into the molecular bases of inherited forms of CL have refined their classification[74,75] (Table 97.7). Mutations in the elastin gene (*ELN*) that lead to qualitative as well as quantitative abnormalities in this protein have been identified as the cause of an autosomal dominant form of CL[76]. Defects in several genes can underlie autosomal recessive CL (ARCL), which tends to be more severe and is divided into groups with different patterns of extracutaneous involvement. ARCL type 1 features potentially fatal involvement of the lungs, vascular abnormalities, and gastrointestinal/genitourinary diverticula, whereas ARCL types 2 and 3 (de Barsy syndrome) are characterized by craniofacial anomalies and delayed growth and development (see Table 97.7).

Fibulins are calcium-dependent glycoproteins that stabilize ECM networks and provide support for elastic fiber assembly. Biallelic mutations in the genes that encode fibulin 5 and fibulin 4 (EGF-containing fibulin-like extracellular matrix protein 2) cause ARCL types 1A and 1B, respectively; a heterozygous duplication within the fibulin 5 gene was also found to underlie CL in one patient[77–79]. Mutations in the latent TGF-β binding protein-4 gene (*LTBP4*) result in ARCL type 1C, which is characterized by severe pulmonary, gastrointestinal, and genitourinary involvement[80]. LTBP4 is an ECM protein that binds to fibrillin and controls the bioavailability of TGF-β, and LTBP4 deficiency leads to aberrant TGF-β activity and defective elastic fiber assembly in many tissues (see Fig. 95.6).

Defects in several intracellular proteins that play a role in metabolic pathways underlie other forms of ARCL. Variable glycosylation abnormalities result from biallelic mutations in *ATP6V0A2*, *ATP6V1E1*, and *ATP6V1A*, which encode subunits of the vacuolar H^+-ATPase, with a phenotypic spectrum that includes ARCL types 2A, 2C, and 2D and features facial dysmorphism, microcephaly, joint hypermobility, and delayed growth and development[75,81]. Mutations in the genes encoding the mitochondrial enzymes pyrroline-5-carboxylate reductase 1 (*PYCR1*) and pyrroline-5-carboxylate synthetase (*P5CS/ALDH18A1*) cause ARCL types 2B/3B and 3A, respectively, with prominent progeroid features and neurodevelopmental manifestations thought to be related to mitochondrial dysfunction[82] (see Table 97.7). *PYCR1* mutations may also lead to features of EDS (e.g. joint hypermobility) and osteogenesis imperfecta[83]. These enzymes are critical for the biosynthesis of proline, which is a major amino acid in collagen and plays a role in an oxidative cycle important to cellular metabolism. In PYCR1 deficiency, there is increased apoptosis of fibroblasts following oxidative stress.

An alternate pathogenic mechanism for CL, in particular acquired variants, is enhanced degradation of elastic fibers. Sagging of the skin, usually with little or no associated internal organ involvement, can develop in the weeks to months following the onset of an inflammatory skin condition such as a drug reaction, chronic urticaria, or Sweet syndrome (Table 97.8). In these cases, release of elastases into the extracellular milieu by inflammatory cells (e.g. neutrophils, monocytes/macrophages) leads to proteolytic degradation of elastic fibers[84]. Generalized or localized CL can develop following a Sweet syndrome-like neutrophilic dermatosis (referred to as Marshall syndrome) and some of these patients may have increased susceptibility to proteolysis due to α_1-antitrypsin deficiency. Immunopathogenic mechanisms may play a role in some cases of acquired CL, as evidenced by the occurrence of acral or generalized CL in association with monoclonal gammopathies and observation of IgG, IgA, or amyloid deposition on elastic fibers in lesional skin[85,86]. In addition, there may be an underlying genetic susceptibility for the development of CL, e.g. polymorphisms or "mild" mutations in the elastin and/or fibulin 5 genes[87].

CL-like cutaneous changes as well as elastosis perforans serpiginosa and PXE-like findings have been observed in patients treated for a prolonged period with high-dose D-penicillamine for conditions such as Wilson disease or cystinuria. D-penicillamine can interfere with elastin cross-linking by two mechanisms. First, D-penicillamine is a copper chelator and can lower serum copper levels, which reduces the activity of lysyl oxidase, an enzyme required for elastin cross-linking (see Ch. 95)[88]. Second, D-penicillamine can chemically block the allysine and lysine residues that come together to form desmosine cross-links. Because of these actions, newly synthesized elastin molecules do not become stably cross-linked. Instead, they are subject to rapid proteolysis, thus precluding the synthesis of functional elastic fibers.

Clinical Features

All forms of CL are characterized by loose, sagging skin with reduced elasticity and resilience. This often gives the affected patient an "aged" facial appearance with down-slanting palpebral fissures and a long philtrum (Fig. 97.10). Cutaneous findings are present at birth in most heritable forms of CL but may develop later in life in autosomal dominant as well as acquired variants. The laxity and wrinkling usually progress over time, although improvement of the skin with age has been noted in ARCL type 2A. Skin involvement is frequently generalized; however, it can be primarily acral, especially in ARCL type 2B or acquired CL.

In some patients with CL, clinical manifestations are limited to the skin, and the phenotype is primarily of cosmetic concern. In other patients, the cutaneous findings are associated with prominent extracutaneous features, which can include emphysema, umbilical and inguinal hernias, gastrointestinal and vesicourinary tract diverticula, arterial and cardiac valvular abnormalities, skeletal or joint involvement, and delayed growth and development. The extracutaneous manifestations, particularly pulmonary complications, can cause considerable morbidity and mortality[89]. Cutaneous and extracutaneous features of specific types of heritable CL are summarized in Table 97.7.

Generalized acquired CL without an identifiable trigger may be clinically indistinguishable from milder heritable forms of CL, e.g.

Downloaded for Anonymous User (n/a) at Egyptian Knowledge Bank from ClinicalKey.com by Elsevier on March 10, 2024. For personal use only. No other uses without permission. Copyright ©2024. Elsevier Inc. All rights reserved.

HERITABLE FORMS OF CUTIS LAXA AND RELATED CONDITIONS					
Disorder	**Inheritance**	**Gene**	**Protein**	**Distribution of cutis laxa**	**Additional features**
Heritable forms of cutis laxa					
ADCL	AD*	*ELN*	Elastin	Generalized	• Cardiac valve abnormalities, aortic dilatation (variable) • Emphysema (uncommon) • Hernias†
		FBLN5 (single patient reported)	Fibulin 5		
ARCL type 1A	AR	*FBLN5*	Fibulin 5	Generalized; large ears with prominent lobes	• Pulmonary emphysema • Stenoses of the supravalvular aorta and pulmonary arteries • Gastrointestinal and vesicourinary diverticula, hernias† • Micrognathia
ARCL type 1B	AR	*FBLN4/EFEMP2*	Fibulin 4	Generalized but less pronounced; may favor skin folds	• Arterial or aortic tortuosity/aneurysms; aortic isthmus stenosis • Joint hypermobility, arachnodactyly, fractures, high arched palate, micrognathia
ARCL type 1C (Urban–Rifkin–Davis syndrome)	AR	*LTBP4*	Latent TGF-β binding protein-4	Generalized	• Emphysema (severe, often fatal) • Pulmonary arterial stenosis, valvular defects • GI and GU malformations (diverticula, rupture risk) • Micrognathia, large fontanelles • Joint hypermobility, hypotonia • Bitemporal hypotrichosis
ARCL type 2A (Debré type; allelic to wrinkly skin syndrome)	AR	*ATP6V0A2*	Vacuolar H^+-ATPase V0, subunit A2	Generalized; may favor abdomen and dorsal hands; improves over time	• Translucent skin with prominent veins • High myopia (2A); corneal opacities & cataracts (3A/B, PADCL) • Facial dysmorphism‡; triangular face with more progeroid appearance (2B, 3A/B); large fontanelles • Microcephaly, partial pachygyria (2A), absent corpus callosum (2B) • Intellectual disability; seizures, neurologic degeneration (2A); dystonia/athetosis (3A/B) • Congenital hip dysplasia, joint hypermobility, hypotonia, scoliosis, short stature; osteopenia (2B, 3A/B) • Cranial arterial tortuosity (3A, PADCL) • O- and N-glycosylation defect (2A¶)
ARCL types 2B and 3B (de Barsy syndrome B)	AR	*PYCR1*	Pyrroline-5-carboxylate reductase 1	Generalized; may favor dorsal hands/feet or improve over time; occasionally fat pads (e.g. on buttocks; 3A)	
ARCL type 3A (de Barsy syndrome A) and Progeroid ADCL (PADCL)	AR (3A) AD (PADCL)	*P5CS/ALDH18A1*	Pyrroline-5-carboxylate synthetase		
ARCL types 2C and 2D	AR	*ATP6V1E1* (2C) *ATP6V1A* (2D)	Vacuolar H^+-ATPase V1, subunits E1 and A	Generalized with sparse or subcutaneous fat; large skin folds on extremities, fat pads on buttocks; may improve over time (2D)	• Pneumothorax • Cardiac abnormalities, aortic dilation • "Mask-like" triangular face, hypotonia; variable hip dysplasia, marfanoid habitus • Neurodevelopmental abnormalities (2D)
Gerodermia osteodysplastica (geroderma osteodysplasticum)	AR	*GORAB*	Golgin, RAB6-interacting	Primarily on dorsal hands/feet	• Malar hypoplasia, prognathism, oblique furrow lateral to eyebrows • Joint hypermobility • Osteoporosis, fractures, dwarfism
Occipital horn syndrome	X-R	*ATP7A*	ATPase, Cu^{2+}-transporting, α-polypeptide	Generalized, most pronounced on face and neck	• Easy bruising, coarse hair (variable) • Arterial tortuosity • Chronic diarrhea; bladder diverticula • Long face, high forehead, hooked nose • Developmental delay • Wedge-shaped occipital calcifications • Joint hypermobility
Macrocephaly, alopecia, CL, and scoliosis (MACS)	AR	*RIN2*	RAS and RAB interactor 2	Generalized, most pronounced on face	• Sparse scalp hair • Gingival hypertrophy, facial dysmorphism • Macrocephaly • Scoliosis, joint hypermobility

Table 97.7 Heritable forms of cutis laxa (CL) and related conditions.

Continued

Downloaded for Anonymous User (n/a) at Egyptian Knowledge Bank from ClinicalKey.com by Elsevier on March 10, 2024. For personal use only. No other uses without permission. Copyright ©2024. Elsevier Inc. All rights reserved.

HERITABLE FORMS OF CUTIS LAXA AND RELATED CONDITIONS					
Disorder	**Inheritance**	**Gene**	**Protein**	**Distribution of cutis laxa**	**Additional features**
Other heritable conditions that feature lax and/or redundant skin					
Arterial tortuosity syndrome	AR	*SLC2A10 (GLUT10)*	Solute carrier family 2, member 10 (a glucose transporter)	Generalized; soft, hyperextensible skin has also been described	• Telangiectasias on cheeks (variable) • Arterial tortuosity • Long face, micrognathia, high-arched palate • Joint hypermobility and contractures
Larsen-like syndrome	AR	*B3GAT3*	Glucuronosyltransferase I	Wrinkled acral skin	• Joint dislocations, craniofacial dysmorphism, short stature • Congenital heart defects
Costello syndrome	AR	*HRAS*	HRAS	Variable, especially on hands and feet	• Deep palmoplantar creases, acanthosis nigricans, periorificial papillomas • Curly or sparse hair, coarse facies • Cardiac malformations • Intellectual disability, short stature • Risk of malignancies, e.g. rhabdomyosarcoma
Donohue syndrome ("leprechaunism"; see Ch. 101)	AR	*INSR*	Insulin receptor	Variable	• Generalized lipodystrophy, hypertrichosis, acanthosis nigricans • Insulin resistance • Distinctive "elfin" facies • Severe growth delay
Finnish-type amyloidosis	AD	*GSN*	Gelsolin	Generalized	• Corneal dystrophy • Polyneuropathy
Cranioectodermal dysplasia (Sensenbrenner syndrome)	AR	*IFT122* *IFT43*	Intraflagellar transport proteins 122 and 43	Generalized; redundant skin folds at neck, ankles, and wrists	• Sparse, fine hair; short, broad nails • Narrow thorax, short proximal limbs, joint hypermobility, brachydactyly, dolichocephaly, dysmorphic facies, dental anomalies • Nephronophthisis, hepatic fibrosis, retinal dystrophy
		WDR35 *WDR19*	WD repeat domain 35 and 19		
Circumferential skin creases, Kunze type	AD, AR	*MAPRE2*	Microtubule-associated protein RP/EB family member 2	Multiple circumferential creases/folds of skin on the extremities (see Fig. 97.13) > neck > trunk (excess rather than lax skin); may resolve over time	• Cleft palate, short stature, dysmorphic facies (e.g. epicanthal folds, small eyes), overfolded helices • Intellectual disability
	AD	*TUBB*	Tubulin-β class I		
Nonsyndromic "Michelin tire baby"	AD	?	?		• Affected skin may have excess fat or smooth muscle, and the latter is often associated with hypertrichosis; elastic fibers are usually normal (fragmentation noted in only one report)

*An AR form of cutis laxa due to a homozygous elastin mutation has been reported in two related families.
†E.g. inguinal, umbilical, diaphragmatic.
‡Features may include a broad forehead and midfacial hypoplasia as well as findings related to the lax skin (e.g. down-slanting palpebral fissures, long philtrum).
¶Can be assessed via analysis of the glycosylation of serum sialotransferrin ± apolipoprotein C-III via isoelectric focusing.

Table 97.7 Heritable forms of cutis laxa (CL) and related conditions. CL can also occur in Williams–Beuren syndrome, which results from deletion of multiple contiguous genes that include *ELN*. In addition to ARCL types 2A and 2C, CL can occur in other congenital disorders of glycosylation, e.g. due to mutations in a component of oligomeric Golgi complex 7 (*COG7*; multiple-system malformations) or steroid 5-α-reductase 3 (*SRD5A3*; also ichthyosis, ocular colobomas, and midline brain malformations). Transaldolase deficiency can present with neonatal CL (generalized or of the forehead) that improves over time as well as hypertrichosis, hepatosplenomegaly, hemolytic anemia, and GU malformations. Features of cutis laxa have also been reported in PURA syndrome. "Neonatal CL with a marfanoid phenotype" was described in an infant who lacked immunohistochemical evidence of laminin-β1 in the skin. AD, autosomal dominant; *ALDH18A1*, aldehyde dehydrogenase 18 family, member A1; AR, autosomal recessive; *EFEMP2*, EGF-containing fibulin-like extracellular matrix protein 2; GI, gastrointestinal; GU, genitourinary; TGF, transforming growth factor; X-R, X-linked recessive.

late-onset autosomal dominant CL. Generalized or localized forms of acquired CL can also occur in association with a plasma cell dyscrasia (see Fig. 97.10B), as a consequence of drug intake (particularly penicillamine), and subsequent to a systemic or cutaneous inflammatory disorder (see Table 97.8). In the latter situation, the inflammatory reaction is followed by progressive sagging of the skin, which can become extensive and lead to a prematurely aged appearance. Acquired CL most commonly develops in adults and when it presents with generalized skin involvement, often beginning on the face and neck, there can be associated internal manifestations such as emphysema and diverticula (e.g. gastrointestinal, vesicourinary). Occasionally, localized CL is found predominantly around the eyes (blepharochalasis) or on the distal extremities, particularly the palms and soles (Fig. 97.11). Marshall syndrome refers to CL in association with a Sweet syndrome-like neutrophilic dermatosis, and it occurs primarily in infants and young children[90].

Pathology

In the skin of patients with CL, the characteristic histopathologic feature is sparse and/or fragmented elastic fibers (Fig. 97.12). This ranges from virtual absence of elastic fibers in a newborn with severe CL (e.g. ARCL type 1) to fragmentation but normal density of fibers in late-onset autosomal dominant CL. Electron microscopy shows irregular

Downloaded for Anonymous User (n/a) at Egyptian Knowledge Bank from ClinicalKey.com by Elsevier on March 10, 2024. For personal use only. No other uses without permission. Copyright ©2024. Elsevier Inc. All rights reserved.

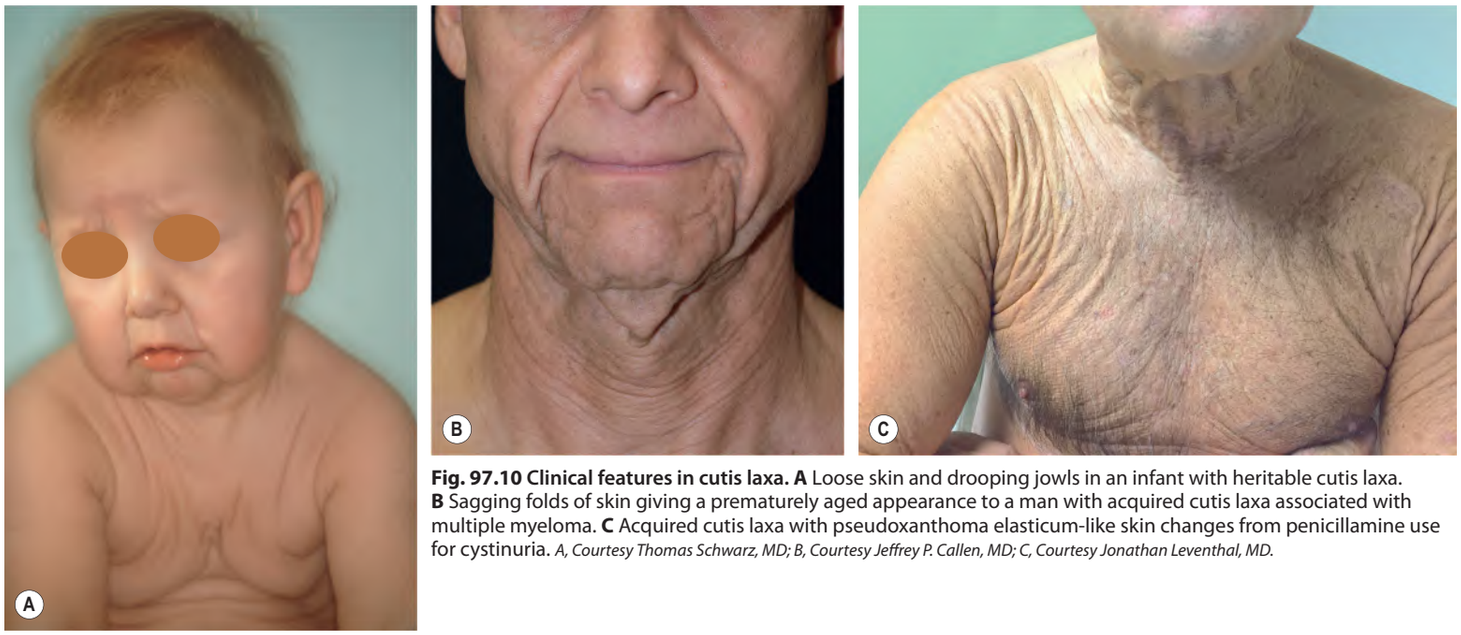

Fig. 97.10 Clinical features in cutis laxa. A Loose skin and drooping jowls in an infant with heritable cutis laxa. **B** Sagging folds of skin giving a prematurely aged appearance to a man with acquired cutis laxa associated with multiple myeloma. **C** Acquired cutis laxa with pseudoxanthoma elasticum-like skin changes from penicillamine use for cystinuria. *A, Courtesy Thomas Schwarz, MD; B, Courtesy Jeffrey P. Callen, MD; C, Courtesy Jonathan Leventhal, MD.*

ACQUIRED CUTIS LAXA: ASSOCIATED CONDITIONS
Skin disorders
• Urticaria and/or angioedema • Drug eruptions (e.g. due to penicillin or an SSRI) • Sweet syndrome-like eruptions (Marshall syndrome*) • Urticarial vasculitis • Arthropod bite reactions • Erythema multiforme • Dermatitis herpetiformis • Lupus panniculitis • Interstitial granulomatous dermatitis • Cutaneous mastocytosis • Cutaneous lymphoma
Extracutaneous inflammatory disorders
• Rheumatoid arthritis • Systemic lupus erythematosus • Nephrotic syndrome • Celiac disease • Sarcoidosis
Hematologic disorders
• Monoclonal gammopathy (especially acral CL; underlying plasma cell dyscrasia)† • Congenital hemolytic anemia
Infectious diseases
• Febrile viral syndrome • *Borrelia burgdorferi* infection • Syphilis • Leprosy
Drug intake (also see drug eruptions above)
• Penicillamine • Isoniazid
*Occurs primarily in infants and young children and is referred to as type II acquired CL, with other forms of acquired CL classified as type I. †Commonly associated with systemic amyloidosis in setting of multiple myeloma.

Table 97.8 Acquired cutis laxa (CL): associated conditions. Generalized or localized CL (including Marshall syndrome) can occur in the setting of α_1-antitrypsin deficiency. SSRI, selective serotonin reuptake inhibitor.

Fig. 97.11 Idiopathic acral localized acquired cutis laxa. The pulp of the digits has loose redundant skin (**A**) and pressure can produce a depression (**B**). The only abnormal finding was an elevated ANA titer. *Courtesy Luis Requena, MD.*

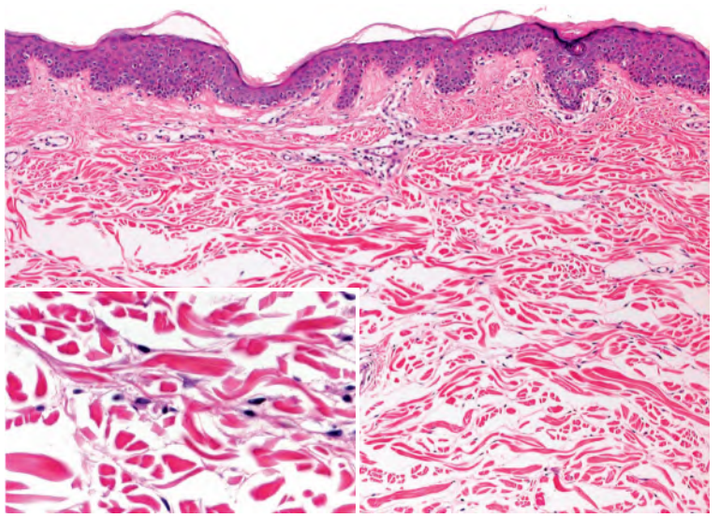

Fig. 97.12 Histologic features of cutis laxa. Dermal elastic fibers are sparse and fragmented. *Courtesy Lorenzo Cerroni, MD.*

fragmentation of the elastic fiber structure. In some patients, elastic fiber abnormalities are accompanied by alterations in collagen fibers, which likely reflect a general perturbation of the ECM and mechanical properties of the skin due to the primary elastic fiber defect.

Differential Diagnosis

Clinical findings similar to CL can develop as a consequence of the normal skin aging. In contrast to CL, the hyperextensible skin of patients with EDS retains elasticity and recoil, with the exception of

Downloaded for Anonymous User (n/a) at Egyptian Knowledge Bank from ClinicalKey.com by Elsevier on March 10, 2024. For personal use only. No other uses without permission. Copyright ©2024. Elsevier Inc. All rights reserved.

the rare dermatosparaxis type. Skin fragility and bruising represent additional features of EDS but not CL. In PXE and the related PXE-like disorder with multiple coagulation factor deficiency, the skin can be loose and sagging without recoil; however, the primary papular lesions at the predilection sites distinguish these conditions from CL.

Mid-dermal elastolysis is an acquired disorder with a predilection for young and middle-aged women that is characterized by circumscribed or diffuse areas of fine wrinkling, most often in sun-exposed sites on the upper trunk, lateral neck, and upper arms (see Ch. 99)[91]. It features the pathognomonic histopathologic finding of a band-like loss of elastic fibers in the mid dermis. Anetoderma presents as focal areas of flaccid skin (typically 1 to 2 cm in diameter) with loss of elastic tissue and may have an antecedent inflammatory process. It is histologically and ultrastructurally identical to CL and may be regarded as a variant of acquired localized CL with smaller, circumscribed lesions.

Additional rare syndromes that can present with lax skin and elastic fiber abnormalities are outlined in Table 97.7[92]. Of note, the "Michelin tire baby" phenotype of congenital circumferential skin creases on the extremities may be reminiscent of CL, but the folds reflect excess tissue rather than cutaneous laxity (Fig. 97.13).

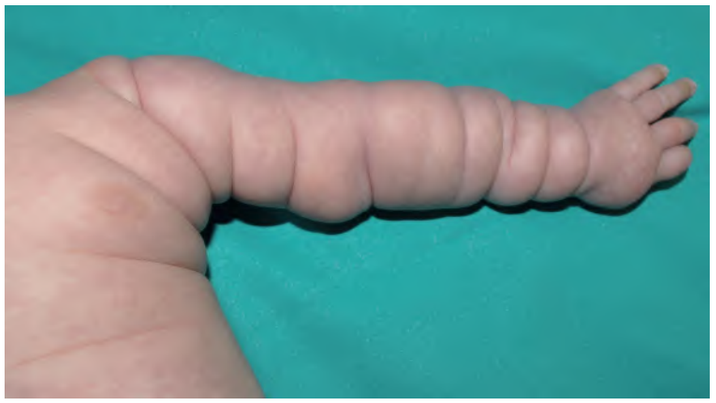

Fig. 97.13 "Michelin tire baby" phenotype. Note the circumferential skin creases on the extremities. *Courtesy Antonio Torrelo, MD.*

Treatment

The redundant and sagging skin may be of major cosmetic concern to patients with CL, and reconstructive surgery can provide improvement with significant psychosocial benefit. Surgical wounds heal with scars that have a normal appearance and tensile strength. However, sagging may reoccur, necessitating additional surgical procedures. The associated internal organ involvement requires appropriate care through a multidisciplinary approach. All patients should have a baseline echocardiogram and pulmonary assessment, with further investigations such as urinary tract ultrasound (ARCL type 1) and neurologic evaluation (ARCL types 2/3) depending on the subtype and clinical findings[75].

Additional figures and table, Five-point joint hypermobility questionnaire, available in our eBook (see inside front cover for access code).

REFERENCES

1. Sybert VP. *Genetic Skin Disorders*, Vol. 33. Oxford: Oxford University Press; 1997.
2. Pulkkinen L, Ringpfeil F, Uitto J. Progress in heritable skin diseases: molecular bases and clinical implications. *J Am Acad Dermatol*. 2002;47:91–104.
3. McKusick V. *Heritable Disorder of Connective Tissue*. St. Louis: Mosby; 1972:475.
4. Pinnell SR, Krane SM, Kenzora JE, Glimcher MJ. A heritable disorder of connective tissue: hydroxylysine-deficient collagen disease. *N Engl J Med*. 1972;286:1013–1020.
5. Beighton P, De Paepe A, Steinmann B, et al. Ehlers-Danlos syndromes: revised nosology, Villefranche, 1997. Ehlers-Danlos National Foundation (USA) and Ehlers-Danlos Support Group (UK). *Am J Med Genet*. 1998;77:31–37.
6. Malfait F, De Paepe A. The Ehlers-Danlos syndrome. *Adv Exp Med Biol*. 2014;802:129–143.
7. Malfait F, Francomano C, Byers P, et al. The 2017 international classification of the Ehlers-Danlos syndromes. *Am J Med Genet C Semin Med Genet*. 2017;175:8–26.
8. Myllyharju J, Kivirikko KI. Collagens and collagen-related diseases. *Ann Med*. 2001;33:7–21.
9. Pepin MG, Schwarze U, Rice KM, et al. Survival is affected by mutation type and molecular mechanism in vascular Ehlers-Danlos syndrome (EDS type IV). *Genet Med*. 2014;16:881–888.
10. Baumann M, Giunta C, Krabichler B, et al. Mutations in FKBP14 cause a variant of Ehlers-Danlos syndrome with progressive kyphoscoliosis, myopathy, and hearing loss. *Am J Hum Genet*. 2012;90:201–216.
11. Schalkwijk J, Zweers MC, Steijlen PM, et al. A recessive form of the Ehlers-Danlos syndrome caused by tenascin-X deficiency. *N Engl J Med*. 2001;345:1167–1175.
12. Kapferer-Seebacher I, Pepin M, Werner R, et al. Periodontal Ehlers-Danlos syndrome is caused by mutations in C1R and C1S, which encode subcomponents C1r and C1s of complement. *Am J Hum Genet*. 2016;99:1005–1014.
13. Beighton P, Solomon L, Soskolne CL. Articular mobility in an African population. *Ann Rheum Dis*. 1973;32:413–418.
14. Steinmann B, Royce PM. *Connective Tissue and its Heritable Disorders*. *Molecular Genetic, and Medical Aspects*. New York: Wiley-Liss; 1993.
15. Bowen JM, Sobey GJ, Burrows NP, et al. Ehlers-Danlos syndrome, classical type. *Am J Med Genet C Semin Med Genet*. 2017;175:27–39.
16. Atzinger CL, Meyer RA, Khoury PR, et al. Cross-sectional and longitudinal assessment of aortic root dilation and valvular anomalies in hypermobile and classic Ehlers-Danlos syndrome. *J Pediatr*. 2011;158:826–30. e1.
17. De Wandele I, Rombaut L, Leybaert L, et al. Dysautonomia and its underlying mechanisms in the hypermobility type of Ehlers-Danlos syndrome. *Semin Arthritis Rheum*. 2014;44:93–100.
18. Castori M, Tinkle B, Levy H, et al. A framework for the classification of joint hypermobility and related conditions. *Am J Med Genet C Semin Med Genet*. 2017;175:148–157.
19. Pepin M, Schwarze U, Superti-Furga A, et al. Clinical and genetic features of Ehlers-Danlos syndrome type IV, the vascular type. *N Engl J Med*. 2000;342:673–680.
20. Green C, Ghali N, Akilapa R, et al. Classical-like Ehlers-Danlos syndrome: a clinical description of 20 newly identified individuals with evidence of tissue fragility. *Genet Med*. 2020;22:1576–1582.
21. Angwin C, Ghali N, Baker D, et al. Electron microscopy in the diagnosis of Ehlers-Danlos syndromes: correlation with clinical and genetic investigations. *Br J Dermatol*. 2020;182:698–707.
22. Murray ML, Pepin M, Peterson S, et al. Pregnancy-related deaths and complications in women with vascular Ehlers-Danlos syndrome. *Genet Med*. 2014;16:874–880.
23. Ong KT, Perdu J, De Backer J, et al. Effect of celiprolol on prevention of cardiovascular events in vascular Ehlers-Danlos syndrome: a prospective randomised, open, blinded-endpoints trial. *Lancet*. 2010;376:1476–1484.
24. Gorosabel MC, Dubacher N, Meienberg J, et al. Vascular Ehlers-Danlos syndrome: can the beneficial effect of celiprolol be extrapolated to bisoprolol? *Eur Heart J Cardiovasc Pharmacother*. 2020;6:199–200.
25. Speake D, Dvorkin L, Vaizey CJ, et al. Management of colonic complications of type IV Ehlers-Danlos syndrome: a systematic review and evidence-based management strategy. *Colorectal Dis*. 2020;22:129–135.
26. Darier J. Pseudo-xanthome élastique. *III Congrès Intern de Dermat de Londres*. 1896;5:289–295.
27. Grönblad E. Angioid streaks - pseudoxanthoma elasticum. *Acta Ophthalmol*. 1929;7:329.
28. Strandberg J. Pseudoxanthoma Elasticum. *Z Haut Gechlechtskr*. 1929;31:689–694.
29. Ringpfeil F, Lebwohl MG, Christiano AM, et al. Pseudoxanthoma elasticum: mutations in the MRP6 gene encoding a transmembrane ATP-binding cassette (ABC) transporter. *Proc Natl Acad Sci U S A*. 2000;97:6001–6006.
30. Ringpfeil F, McGuigan K, Fuchsel L, et al. Pseudoxanthoma elasticum is a recessive disease characterized by compound heterozygosity. *J Invest Dermatol*. 2006;126:782–786.
31. Neldner KH. Pseudoxanthoma elasticum. *Clin Dermatol*. 1988;6:1–159.
32. Jansen RS, Kucukosmanoglu A, de Haas M, et al. ABCC6 prevents ectopic mineralization seen in pseudoxanthoma elasticum by inducing cellular nucleotide release. *Proc Nat Acad Sci USA*. 2013;110:20206–20211.
33. Li Q, Huang J, Pinkerton AB, et al. Inhibition of tissue-nonspecific alkaline phosphatase attenuates ectopic mineralization in the Abcc6(-/-) mouse model of PXE but not in the Enpp1 mutant mouse models of GACI. *J Invest Dermatol*. 2019;139:360–368.
34. Nitschke Y, Rutsch F. Generalized arterial calcification of infancy and pseudoxanthoma elasticum: two sides of the same coin. *Front Genet*. 2012;3:302.
35. Li Q, Brodsky JL, Conlin L, et al. Mutations in the ABCC6 gene as a cause of generalized arterial calcification of infancy: genotypic overlap with pseudoxanthoma elasticum. *J Invest Dermatol*. 2014;134:658–665.
36. Saeidian AH, Youssefian L, Huang JH, et al. Genetic heterogeneity of heritable ectopic mineralization disorders in a large international cohort. *Genet Med*. 2022;24:75–86.
37. Markello TC, Pak LK, St Hilaire C, et al. Vascular pathology of medial arterial calcifications in NT5E deficiency: implications for the role of adenosine in pseudoxanthoma elasticum. *Mol Genet Metab*. 2011;103:44–50.
38. Li Q, Price TP, Sundberg JP, et al. Juxta-articular joint-capsule mineralization in CD73 deficient mice: similarities to patients with NT5E mutations. *Cell Cycle*. 2014;13:2609–2615.
39. Vanakker OM, Martin L, Gheduzzi D, et al. Pseudoxanthoma elasticum-like phenotype with cutis laxa and multiple coagulation factor deficiency represents a separate genetic entity. *J Invest Dermatol*. 2007;127:581–587.
40. Li Q, Grange DK, Armstrong NL, et al. Mutations in the GGCX and ABCC6 genes in a family with pseudoxanthoma elasticum-like phenotypes. *J Invest Dermatol*. 2009;129:553–563.
41. Ralph D, van de Wetering K, Uitto J, Li Q. Inorganic pyrophosphate deficiency syndromes and potential treatments for pathologic tissue calcification. *Am J Pathol*. 2022;192:762–770.
42. Lebwohl M, Lebwohl E, Bercovitch L. Prominent mental (chin) crease: a new sign of pseudoxanthoma elasticum. *J Am Acad Dermatol*. 2003;48:620–622.
43. Hoppner J, Kornak U, Sinningen K, et al. Autosomal recessive hypophosphatemic rickets type 2 (ARHR2) due to ENPP1-deficiency. *Bone*. 2021;153:116111.
44. Lebwohl M, Phelps RG, Yannuzzi L, et al. Diagnosis of pseudoxanthoma elasticum by scar biopsy in patients without characteristic skin lesions. *N Engl J Med*. 1987;317:347–350.

Downloaded for Anonymous User (n/a) at Egyptian Knowledge Bank from ClinicalKey.com by Elsevier on March 10, 2024. For personal use only. No other uses without permission. Copyright ©2024. Elsevier Inc. All rights reserved.

eFig. 97.1 Molluscoid pseudotumors on the knees in a patient with Ehlers–Danlos syndrome.

eFig. 97.2 Atrophic scar in a patient with the classical type of Ehlers–Danlos syndrome.

eFig. 97.3 Typical facial features of the vascular type of Ehlers–Danlos syndrome. *Courtesy Addenbrooke's Hospital, Cambridge, UK.*

eFig. 97.4 Clinical features of pseudoxanthoma elasticum. Yellowish papules and "cobblestoned" plaques in the antecubital fossa (**A**) and neck (**B**). *A, Courtesy Julie V. Schaffer, MD.*

eFig. 97.5 Mucosal lesions in pseudoxanthoma elasticum. Yellow papules on the inner aspect of the lower lip.

FIVE-POINT JOINT HYPERMOBILITY QUESTIONNAIRE
1. Can you now (or could you ever) place your hands flat on the floor without bending your knees?
2. Can you now (or could you ever) bend your thumb to touch your forearm?
3. As a child, did you amuse your friends by contorting your body into strange shapes or could you do the splits?
4. As a child or teenager, did your shoulder or kneecap dislocate on more than one occasion?
5. Do you consider yourself "double-jointed"?
A "yes" answer to ≥2 questions suggests joint hypermobility, with 80%–85% sensitivity and 80%–90% specificity.

eTable 97.1 Five-point joint hypermobility questionnaire[7]. *Adapted from Hakim AJ, Grahame R. Int J Clin Pract 2003;57:163–6.*

Downloaded for Anonymous User (n/a) at Egyptian Knowledge Bank from ClinicalKey.com by Elsevier on March 10, 2024. For personal use only. No other uses without permission. Copyright ©2024. Elsevier Inc. All rights reserved.